

# Isolated Dextrocardia coexisting with Skeletal Anomalies and Mild Cardiac Anomalies

Type of Article: **Case Report**

\*Eyo .Effiong Ekpe, \*\*Mandu Charles. Ikpe

\*Cardiothoracic Surgery Unit, Department of Surgery, and \*\*Department of Radiology, University of Uyo Teaching Hospital, Uyo, Nigeria.

## ABSTRACT

**Background:** There are various types of dextrocardia presentation, with some more common than others. This case is reported because of the unusual association of dextrocardia with atrial septal aneurysm and skeletal anomalies.

**Methods:** The case records of a 2 day old male who presented at the University of Nigeria teaching hospital, Enugu for care and a review of the literature of the subject was utilized.

**Results:** A case of a 2 day old male baby with isolated dextrocardia is presented. The initial diagnosis was made by chest radiograph and confirmed by echocardiography. There were no associated severe cardiac anomalies.

**Conclusion:** This case is reported as isolated dextrocardia coexisting with skeletal anomalies and mild cardiac anomalies. Extensive skeletal and cardiac evaluation is advised for subjects with dextrocardia, in order to identify all associated anomalies.

**Keywords:** Isolated dextrocardia; skeletal anomalies; coexisting atrial septal aneurysm.

**Correspondence:** Dr E.E. Ekpe

**E-mail:** docekpe@yahoo.com

## INTRODUCTION

Dextrocardia is malpositioning of the heart, with the cardiac apex located in the right hemithorax. There are various types of dextrocardia: Mirror image dextrocardia, isolated dextrocardia and dextrocardia with situs ambiguous. Mirror image dextrocardia is a right sided apex in complete situs inversus, with reversal of the normal position of the heart chambers and the abdominal organs such as the liver and spleen. Isolated Dextrocardia is the right sided cardiac apex with situs solitus and abdominal organs in their normal position. Dextrocardia can also exist in association with situs ambiguous. Here the left and right sided positioning of the abdominal organs are not clearly evident<sup>1</sup>.

Dextrocardia affects males and females in equal frequency. Approximately 0.01% of infants are born with this rare disorder. Apart from dextrocardia being in association with

reversal of the abdominal organs, it can also be associated with skeletal and cardiac anomalies<sup>2</sup>.

Dextrocardia with a normal abdominal situs has a high incidence of association with congenital heart disease than dextrocardia with a reversed abdominal situs<sup>3</sup>. Frequent cardiac anomalies associated with dextrocardia include ventricular septal defect, transposition of the great arteries, atrial septal defects, double outlet right ventricle and juxtaposition of the atrial appendages. This case is reported because of the unusual association of dextrocardia with atrial septal aneurysm and skeletal anomalies.

## CASE REPORT

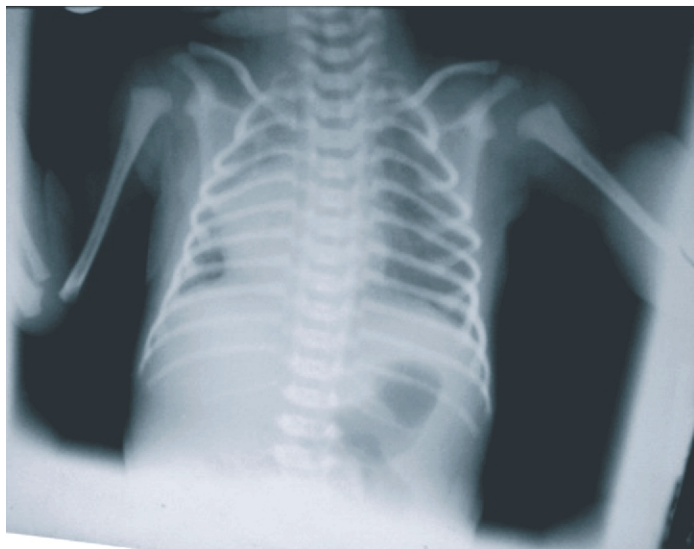
N.O is a 2 day old male baby who was referred to University of Nigeria Teaching Hospital (U.N.T.H), Enugu, from a private medical centre, with presenting complaints of delay in crying following delivery. Patient was delivered about 14 hours prior to presentation by spontaneous vertex delivery, at the gestational age of thirty-eight weeks. There was a delay in crying after delivery and patient had to be resuscitated by suctioning, tactile stimulation, oxygen and hydrocortisone injection, before he started crying. The Apgar score was 6 at 10 minutes. He was referred to U.N.T.H. for further evaluation and treatment. The duration of labour was less than twenty four hours. There was no history suggestive of premature rupture of membrane. His mother was a thirty year old P<sup>4+1</sup> teacher. Mother had antenatal care. There was no history of fever during pregnancy and all drugs taken were prescribed by a Doctor. No history of ingestion of native concoction or herbal medicine.

General examination revealed a full term male neonate, who was conscious, crying excessively, febrile, anicteric, not dehydrated. Cardiovascular system showed tachycardia with heart sounds heard on the right side of the chest. Respiratory system showed mild subcostal recession and tachypnoea. Central nervous, Digestive and Genito- urinary systems were normal. Musculoskeletal examination revealed right sided syndactyly and polydactyly. Laboratory investigations showed PCV of 26%, WBC of 18,400/mm<sup>3</sup>. Neutrophils - 76%, lymphocytes 24%, monocytes 0%. Blood film showed marked neutrophilia with toxic granulations. Blood culture yielded coliform organisms sensitive to ceftaxidine, gentamycin, ciprofloxacin, and resistant to ampicillin, augmentin and cefurozime. A diagnosis of dextrocardia with limb abnormalities (Polydactyly and Syndactyly), birth asphyxia and neonatal sepsis was made.

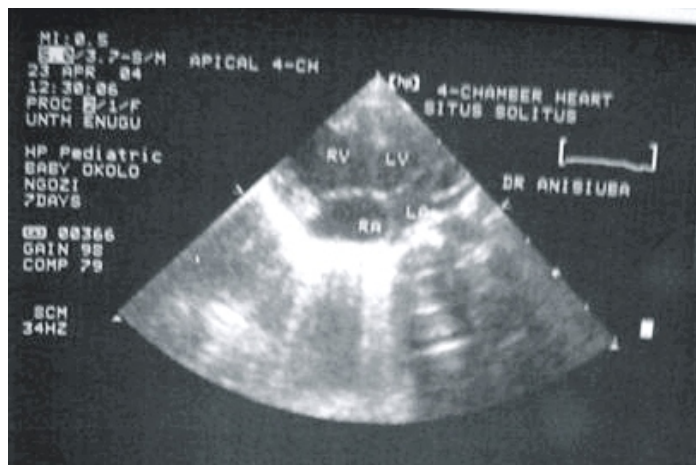
Plain chest radiograph confirmed right sided apex. (Figure 1).

The mediastinum was central, lung fields appeared clear and fundal gas shadow was on the left.. Echocardiography showed a dextroposition of the heart with four chambers, situs solitus, atrial septal aneurysm in the area of foramen ovale but no shunt was seen. Systolic-diastolic flow was seen but no significant turbulence on colour doppler was seen (figure 2). A diagnosis of Dextrocardia with skeletal abnormalities was made. The baby was placed on antibiotics, intravenous fluids, dexamethasone and oxygen therapy. He was also transfused with 30ml of packed red blood cells. The Orthopaedic and

**Figure 1. Posteroanterior Radiograph of the chest showing the apex of the heart on the right side and situs solitus.**



**Figure 2. Apical 4 chamber echocardiogram (with probe reversed) showing a dextroposition of the heart with four chambers, atrial septal aneurysm in the area of foramen ovale. NB: (Probe reversal is a convention for convenience).**



Cardio-thoracic surgery teams later reviewed the baby, who has been stable on conservative management with positive reports of marked improvement and growth.

**DISCUSSION**

Normal human development results in an asymmetrical arrangement of the organs within the chest and abdomen. Typically, the heart lies on the left side of the body

(Levocardia), the liver on the right, the spleen on the left and the left lung has two lobes while the right lung has three lobes. This normal arrangement is known as situs solitus.<sup>4</sup>

Dextrocardia with a normal abdominal situs has a high incidence of association with congenital heart disease<sup>5</sup>. Our patient had isolated dextrocardia with no associated severe cardiac anomalies, but only a mild atrial septal aneurysm.

The diagnosis of Dextrocardia is usually relatively easy and should be detectable through physical examination when a physician picks up heart sounds on the right side of the chest. Diagnoses of associated conditions are more difficult and are best evaluated by imaging techniques.

The preferred modalities for this evaluation include plain chest radiograph which will be able to show the dextrocardia, with the cardiac apex pointing to the right. Computed Tomography (CT) provides good anatomic detail for confirming visceral organ position, cardiac apical position, and great vessel branching. Echocardiography, Magnetic Resonance Imaging (MRI) and Angiography are used to define the position and location of each chamber of the heart and their connections and relations with one another and with the great arteries.

Treatment of Dextrocardia is symptomatic and supportive when needed<sup>6</sup>. In most cases affected individuals can live a normal life without any symptoms or disability. If the condition is associated with other more serious heart malformations, treatment will vary. Associated malformations make it mandatory to depend on medical or surgical alleviations<sup>7</sup>.

Our patient's Dextrocardia was not associated with serious heart malformations. He had atrial septal aneurysm which is a mild heart disorder, and thus did not require any surgical intervention.

**REFERENCES**

1. Van Praagh R, Van Praagh S, Vlad P, Keith JD. Anatomic types of congenital dextrocardia:diagnostic and embryologic implications. *Am J Cardiol.* 1964; 13: 510 - 531.
2. Syburra T, Sutsch G, Huber S, Schnuriger H, Lachat M, Suter J. Isolated dextrocardia in a commercial pilot candidate. *Aviat Space Environ Med.* 2005; 76:137 140.
3. Ito T, Ishitoya T, Abe T, Horiuchi T. Theurapeutic case of multiple heart anomalies with dextrocardia situs inversus complicated by dextrocardia, partial abnormal return of the pulmonary vein, atrial septal defects and defect of the inferior vena cava. *Shujutsu.* 1968; 22 (4) 388 392.
4. Kuramitsu H, Murai M, Nishikawa K. Case of left atrial rhythm associated with mirror image dextrocardia. *Jpn Circ J.* 1967; 31 (5) : 831 834.
5. Miller SW. Symposium on advances in cardiac imaging. *Radiol Clin North Am.* 1985; 23: 587 793.
6. Ekpe EE, Uwah U, Nyong EE. Dextrocardia with situs inversus co-existing with neonatal intestinal obstruction. *Port Harcourt Medical J.* 2008; 2: 177-180.