



## A CASE REPORT ON MULTICENTRIC CASTLEMAN'S DISEASE (MCD) AND CO-MORBIDITIES AT MUHIMBILI NATIONAL HOSPITAL, DARES SALAAM, TANZANIA

\*<sup>1</sup>Amos Rodger Mwakigonja, <sup>2</sup>Zahra Khan, <sup>2</sup>Rose Minja, <sup>3</sup>Abdul Rafey Usmani, <sup>2</sup>Clement Kabakama,

<sup>1</sup>Department of Pathology, Muhimbili University of Health and Allied Sciences (MUHAS), Dar es Salaam, Tanzania.

<sup>2</sup>Department of Internal Medicine, Muhimbili University of Health and Allied Sciences, Muhimbili University of Health and Allied Sciences, Dar es Salaam, Tanzania.

<sup>3</sup>Department of Paediatrics and Child Health, University of Dodoma, Tanzania.

\***Corresponding Author:** Amos Rodger Mwakigonja; **Email:** rodgeramos@yahoo.com

### ABSTRACT

**Background:** Castleman's disease (CD) is a rare pre-cancerous lymphoproliferative disorder comprising at least four poorly understood and heterogeneous hematological disorders/variants sharing a spectrum of common characteristic histopathological features.

**Case Summary:** Here we report a case of multicentric Castleman's disease (MCD) seen in a 55-year old male who presented with fever, frequent urination, thirst, multiple neckswellings as well as night sweats. Furthermore, the patient had history of diabetes mellitus (DM) and systemic hypertension (SH). Imaging revealed splenomegaly. The patient underwent further confirmatory laboratory tests and the diagnosis of MCD was entertained. Furthermore, the patient was given chemotherapy (CHOP) and also opted for surgery; unfortunately, however, the patient died during the procedure.

**Discussion:** There are at least four clinicopathological forms of Castleman's disease namely, unicentric (UCD), multicentric (MCD), idiopathic (iMCD) as well as HHV8 associated-MCD. (1) Our current patient was diagnosed with MCD [which can be Human Herpesvirus type 8 (HHV-8)-associated], and then underwent different therapeutic interventions. Unfortunately, the patient died under physician care partly, due to co-morbidities (DM and SHT) besides the underlying disease (MCD) itself, possibly contributed by delayed presentation to hospital as well as limited experience in caring a rather rare condition in our settings.





**Conclusion:** MCD is rare but has been diagnosed at MNH and may be associated with delayed presentation and/or a missed diagnosis. We recommend regular medical check-ups and self-examination for any enlarged lymph nodes, and when CD is diagnosed, early interventions including screening for HHV-8 and HIV infections as well as treatment may be helpful. Co-morbidities must also be considered when planning surgical interventions in order to get the best treatment outcome.

**Keywords:** Castleman's disease, MCD, HHV-8, HIV, lymphoproliferative disorder

## BACKGROUND

Castleman's disease (CD) is a rare condition of lymph nodes and related tissues which was discovered in the 1950s and was initially termed as giant lymph node hyperplasia and angiofollicular lymph node hyperplasia and thus CD has not yet been described as a malignancy instead, it is classified as a lymphoproliferative (pre-cancerous) disorder.<sup>2</sup> The epidemiology of CD is poorly studied.<sup>1,3</sup> Using an insurance claims database; 6,500 to 7,700 new cases of CD, including 1,650 cases of MCD, are diagnosed every year in the United States.<sup>3</sup> Furthermore, the incidence of childhood Castleman's disease (CD) is reported to be rare in Western communities.<sup>4</sup> Thus CD comprises at least four poorly understood and heterogeneous variants sharing a spectrum of common characteristic histopathological features.<sup>1,3</sup> These disorders include unicentric CD (UCD) which is localized to a single region of lymph nodes (LN), multicentric (MCD) manifesting with systemic inflammatory symptoms and organ dysfunction due to cytokine dysregulation and involves multiple lymph node regions.<sup>3</sup> Furthermore, human herpesvirus 8 (HHV-8) may cause some cases of MCD (HHV-8-associated MCD) in immunocompromised individuals, such as HIV-infected patients.<sup>3</sup> However, over 50% of MCD cases are HIV/HHV-8 negative defined as idiopathic [iMCD]<sup>3,5,6</sup> and lastly, there is polyneuropathy, organomegaly, endocrinopathy, monoclonal plasma cell disorder, skin changes (POEMS)-associated MCD (POEMS-MCD).<sup>1</sup> Treatment of MCD and particularly iMCD is generally challenging, and outcomes can be poor because no established uniform guidelines exist, few systematic studies have been conducted, and no agreed upon response criteria have been described.<sup>3,5</sup> However, during management, CD is often treated with chemotherapy, immunotherapy including rituximab and siltuximab as well as adjuvant radiation therapy.<sup>5</sup> On the other hand, the treatment for UCD includes surgical tumorectomy.<sup>7,8</sup> Furthermore, although



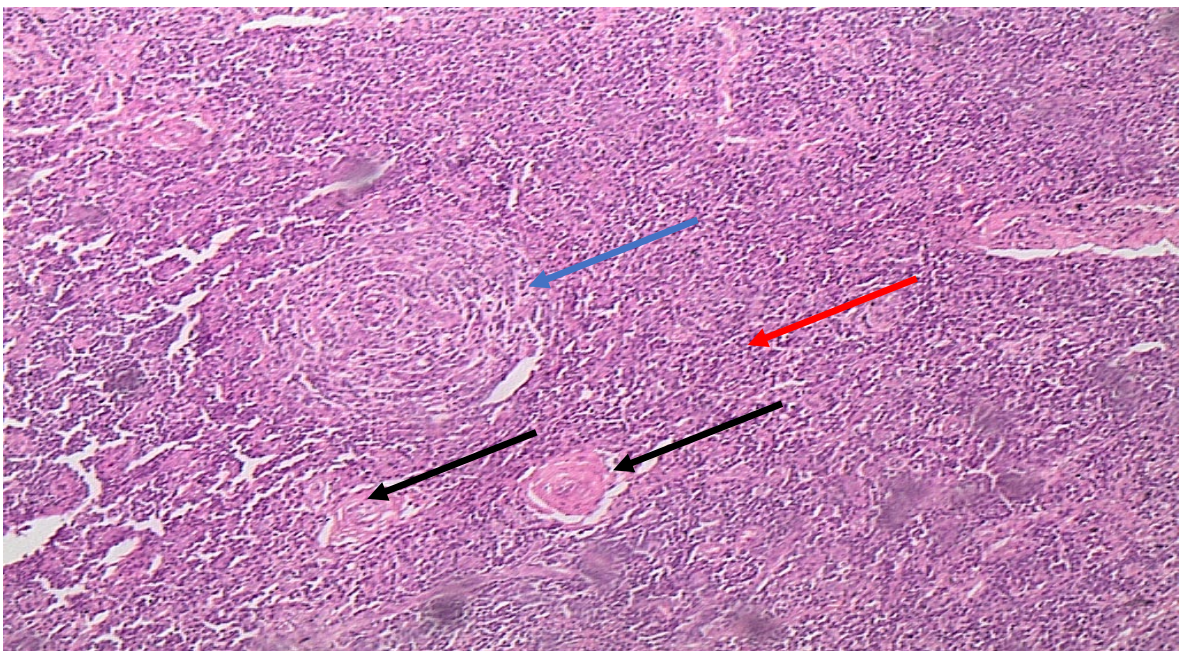
the pathophysiology is not well understood, but it has been postulated that CD leads to involvement of lymph nodes which may then be characterized by abnormal features including small/large germinal follicular dendritic cell (FDC) prominence, hypervascularity, polyclonal plasmacytosis and expansion of polyclonal B cells and T cells.<sup>9,10</sup> Patients sometimes experience inflammatory symptoms believed to be caused by elevated interleukin IL-6. These symptoms typically resolve after lymph node excision.<sup>11</sup> In sub-Saharan Africa particularly Eastern Africa, the epidemiology of CD is not well documented and has been also been associated with some malignancies including Kaposi's sarcoma and certain lymphomas.<sup>4</sup>

Here we report a case of a 55 years old male patient who presented to the Muhimbili National Hospital (MNH), Dar es Salaam, Tanzania, with pyrexia, polyuria, polydipsia, multiple neck swellings and night sweats where he was admitted. The patient also had history of diabetes mellitus (DM) and systemic hypertension (SHT). On objective physical examination, the patient's other findings were unremarkable besides DM type 2 and SHT.

## CASE PRESENTATION

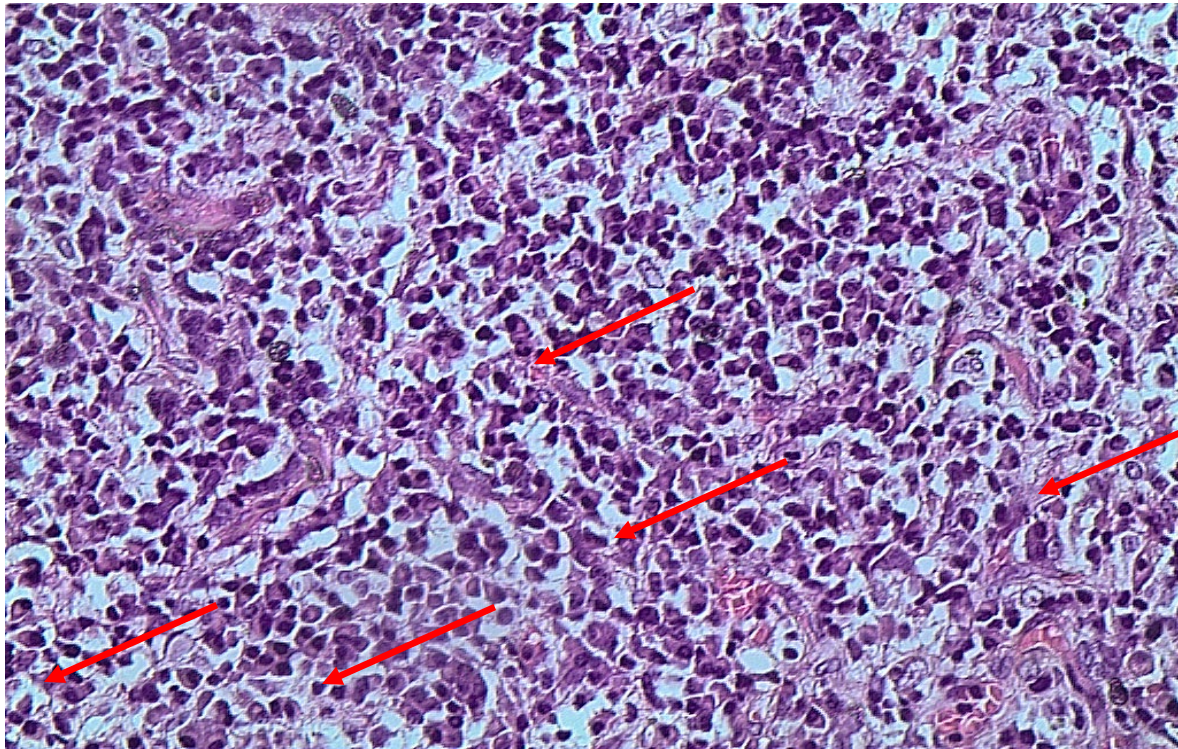
A 55-year old male patient of Swahili descent from Tanga Region, who was a married civil and irrigation engineer, presented with longstanding (six months) symptoms of anaemia, low-grade fever, multiple neck, axillary and inguinal swellings which were increasing and decreasing in size with time, as well as night sweats. Furthermore, the patient had frequent urination and thirst, loss of appetite as well as weight loss. Moreover, the patient had been admitted on and off, at several different hospitals including history of recurrent blood transfusions at Bombo Regional Referral Hospital (RRH), Tanga where he was also diagnosed to have diabetes mellitus and systemic hypertension and was initially started on insulin for the acute phase as well as Losartan. He had been admitted twice during the six months and received blood transfusions (BT) 2 units. In between the Bombo RRH admissions, he was also admitted at the Regency Hospital in Dar es Salaam for 23 days where he was also diagnosed to have hypothyroidism and started L-thyroxine and given ferotone, metfomin and BT 3 units. He was later admitted at MNH where he also received BT 2 units. On physical examination he was very pale (pallor +++), afebrile, not jaundiced, and no finger clubbing. The lymph nodes were enlarged (range 1-4cm), rounded, rubbery, discrete, non-tender and mobile. His BP was 130/98mmhg. Abdominal ultrasonography (USS) revealed mild splenomegaly. Furthermore, lab tests showed normal

blood sugar levels [fasting blood glucose (FBG) 85mg/dl (he was on oral hypoglycaemics) and his complete blood count revealed low Hb (2 g/dl) [See Table 1]. His HIV serostatus was negative and PCR for HHV8 was also negative while the erythrocyte sedimentation rate (ESR) was raised (106mm/hour). Furthermore, we did lymph node biopsy which showed proliferation of follicles with “onion skin” pattern, hyalinized interfollicular blood vessels and extensive proliferation of plasma cells features consistent with multicentric Castleman's disease (MCD). The patient was managed with oral prednisolone 60MG OD together with chemotherapy which included Cyclophosphamide, Hydroxydaunorubicin, Vincristine Sulfate (**Oncovin**), and Prednisone (CHOP). He was on these medications when he died on the 10<sup>th</sup> day of his last admission (at MNH). Below are the images for the lymphoid biopsy sections in figures 1 and 2:



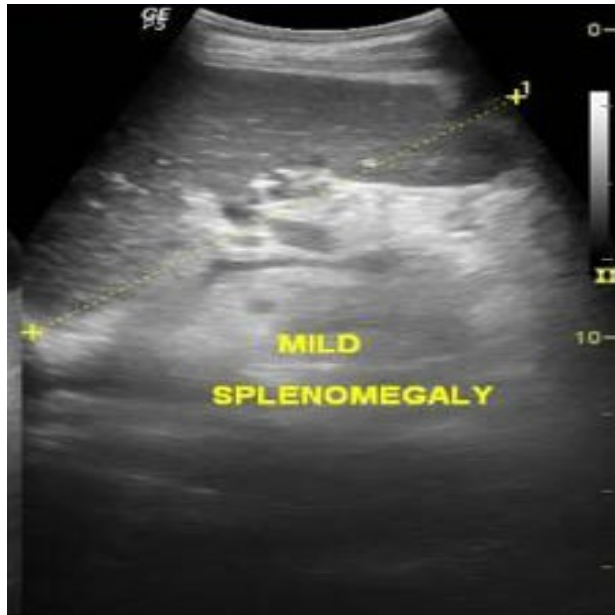
**Figure 1:** A histological (H &E) micrograph showing a follicle displaying the “onion-skin” appearance in the mantle zone (blue arrow) as well as hyalinized interfollicular blood vessels (black arrows) and extensive proliferation of plasma cells (red arrow). This implies an overlap between the Hyaline-Vascular as well as the Plasmablastic Variants of MCD occurring in one patient (x 20 magnification).





**Figure 2:** A histological (H & E) micrograph showing extensive proliferation of plasma cells (red arrows) implying a plasmablastic variant of MCD (x40).

On further clinical and laboratory evaluation to exclude differential diagnoses a chest x-ray together with an abdominal ultrasound (USS) [figures 3 below] were performed which revealed splenomegaly.



**Figure 3:** An abdominal ultrasonography of the patient showing splenomegaly.

The patient was advised to undergo further confirmatory laboratory tests elsewhere since they could not be done at the Central Pathology Laboratory (CPL) at MNH including interleukin 6 (IL-6) and Vascular Endothelial Growth Factor (VEGF) levels, serum protein electrophoresis which were not yet done when he died later.

In summary, we present a 55 years old male engineer of Swahili descent, with 6 months history of generalized waxing and waning lymphadenopathy, B symptoms, anaemia with recurrent BT (7 units in 6 months), hypothyroidism as well as suggestive LN histopathology which allowed the diagnosis of MCD. He was started on chemotherapy including treatment for the co-morbidities. However, since the management plan for MCD includes an option for surgery, the patient and family gave informed consent for the procedure during which (intraoperatively) he died unfortunately, despite best efforts to save his life. This death might have been partly been contributed by the pre-existing DM, systemic hypertension as well as hypothyroidism. The immediate cause of death could have been cardiac arrest upon induction of general anaesthesia due to hypertension with poorly controlled BP, poorly controlled blood sugar as well as possible hormonal (thyroxine) imbalance. A contributory factor could have been long standing severe

anemia with recurrent blood transfusions. Thus the four co-morbidities namely DM, SHT, hypothyroidism and severe chronic anaemia could all have contributed to the death during anaesthesia. Another possible explanation could have been unforeseen drug interactions as he was on antihypertensives, antidiabetics, hormonal replacement therapy, steroids, combination chemotherapy as well as symptomatic treatments.

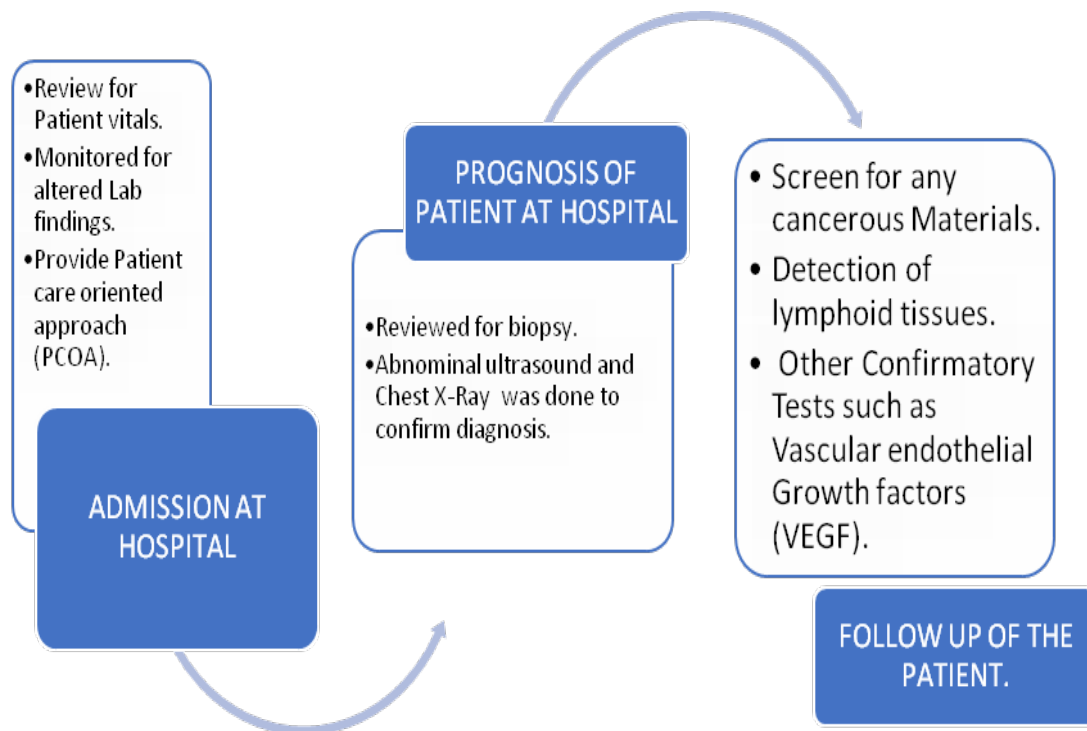


Figure 4: A suggested algorithm or management chart for an MCD patient.



**CLINICAL LABORATORY INVESTIGATIONS REPORT**

**Table 1: Clinical laboratory Test**

<b>Test Parameter</b>	<b>Observed Value</b>	<b>Reference Range</b>
Hemoglobin	13.2g/dL	14g/dL -18g/dL
White blood cells	5.5×10 <sup>3</sup> cells/mm <sup>3</sup>	3.2-9.8×10 <sup>3</sup> cells/mm <sup>3</sup>
Platelet Count	64×10 <sup>3</sup> cell/mm <sup>3</sup>	130-400×10 <sup>3</sup> cell/mm <sup>3</sup>
Hematocrit	38.6%	33-43%
Mean cell volume	108.4fL	76-100fL
Mean cell hemoglobin	36.4pg/cell	27-33pg/cell
Mean cell hemoglobin concentration	33.5g/dL	33-37g/dL
Fasting Blood sugar	85mg/dL	<100mg/dL
Blood urea	26mg/dL	20-40mg/dL
Serum creatinine	1.0mg/dL	0.6-1.2mg/dL
Blood urea nitrogen	10mg/dL	8-18mg/dL
Total Protein	84	60-80g/l
Aspartate aminotransferase	26U/L	0-35U/L
Alanine aminotransferase	17U/L	0-35U/L
Alkaline phosphatase	155U/L	30-120U/L
Bilirubin Total	1.7mg/dL	0.1-1mg/dL
Bilirubin Direct	0.7mg/dL	0-0.2mg/dL
Bilirubin Indirect	1.0mg/dL	0.1-0.8mg/dL
Urine sugar	Nil	Nil
Urine albumin	Nil	Nil
Phosphorous	0.8.	0.7-1.2mmol/l
Potassium	3.7	3.5mmol/L
Albumin	32	35-50g/l

Hemoglobin(Hb);Hematocrit(Hct); Mean cell volume(MCV);Mean cell hemoglobin(MCH), Mean cell hemoglobin concentration(MCHC); Blood urea(BU);Blood urea nitrogen(BUN), Serum





creatinine(Sr.cr); Aspartate aminotransferase(SGOT); Alanine aminotransferase(SGPT), Alkaline phosphates(ALP);

## DISCUSSION AND CONCLUSION

Castleman's disease (CD) is rare in people of Swahili decent in East Africa where reports on the disease are not yet well documented. The microscopic lymph node appearance Benjamin Castleman was the first to describe.<sup>12</sup> However, Human Herpesvirus 8 (HHV-8) associated with multicentric Castleman's disease (MCD) involves multiple regions of enlarged lymph nodes and is associated with flu-like symptoms, abnormal blood counts as well as a dysfunctional liver (elevated LFTs).<sup>13</sup> However, there are at least four clinicopathological forms of Castleman's disease namely, unicentric (UCD), multicentric (MCD), idiopathic MCD (iMCD) as well as POEMS-MCD and furthermore, iMCD can be also be sub-classified into iMCD-thrombocytopenia, ascites, reticulin fibrosis, renal dysfunction, organomegaly (iMCD-TAFRO) or iMCD-not otherwise specified (iMCD-NOS).<sup>(1)</sup> This particular patient seemed to have POEMS-MCD based on the following: generalized lymphadenopathy, splenomegaly (organomegaly), hypothyroidism and diabetes mellitus (endocrinopathy), constitutional (B) symptoms, anemia (abnormal blood counts) as well as the plasmablastic histopathology.<sup>1,3,5,6</sup> Furthermore, since he was HIV and HHV8 negative this was likely to have been an idiopathic MCD or iMCD as well.<sup>1,3,5</sup>

As regards the management, early interventions and thorough diagnostic tests are needed to prevent further complications associated with CD including lymphodegeneration and the possibility of developing Hodgkin lymphoma (HL). The clinical and biological behaviour including the pathogenesis is poorly elucidated however, literature have postulated that a virus, genetic mutations acquired over the course of life, an inherited genetic mutation, or autoimmunity may be involved.<sup>1,3</sup> Furthermore, some researchers speculate that increased production of interleukin-6 (IL-6) as one of the causes and may be involved in the development of MCD.<sup>1,13</sup> IL-6 is a substance normally produced by cells within the lymph nodes plasma cells and in healthy individuals serves to coordinate immune response to infection.<sup>14,15</sup> Thus anti-interleukin-6 monoclonal antibody therapy including siltuximab, tocilizumab and rituximab give very promising therapeutic outcomes in the treatment of MCD.<sup>5,14</sup> However, IL-6 is not elevated in all MCD cases, and thus neutralizing it may not be effective treatment of all patients. It is noteworthy that, the pre-HAART and pre-rituximab prognosis and 5-year survival was less



than 70% previously, which have significantly increased now with the advent of those therapies.

## CONCLUSION

We report rare findings of multicentric Castleman's disease (MCD) probably a POEMS/iMCD case seen in a 55- year old male patient who unfortunately died intraoperatively partly due to co-morbidities (diabetes, hypertension and hypothyroidism). Besides the underlying disease (MCD) itself; possible delayed presentation to hospital as well as limited experience in managing a rather rare condition in our setting may have contributed to this mortality. We recommend regular check-up and self -examination for any enlarged lymph nodes, and when CD is diagnosed early interventions including screening for the Human Herpes Virus-8 (HHV-8) and HIV infection which may be associated with the multicentric Castleman's disease. These measures will be key to preventing further morbidity but also mortality. Furthermore, co-morbidities must also be taken into consideration when planning surgical intervention in order to get the best treatment outcome. And lastly, negativity to HIV/HHV8 testing does not rule out CD.

## REFERENCES

1. Dispenzieri A, Fajgenbaum DC. Overview of Castleman disease. *Blood*. 2020;135(16):1353-64.
2. van Rhee F, Munshi NC. Castleman Disease. *Hematol Oncol Clin North Am*. 2018;32(1):xiii-xiv.
3. Yu L, Tu M, Cortes J, Xu-Monette ZY, Miranda RN, Zhang J, et al. Clinical and pathological characteristics of HIV- and HHV-8-negative Castleman disease. *Blood*. 2017;129(12):1658-68.
4. Taylor KL, Kaschula RO. Castleman's disease in children: the experience of a children's hospital in Africa. *Pediatr Pathol Lab Med*. 1995;15(6):857-68.
5. van Rhee F, Voorhees P, Dispenzieri A, Fossa A, Srkalovic G, Ide M, et al. International, evidence-based consensus treatment guidelines for idiopathic multicentric Castleman disease. *Blood*. 2018;132(20):2115-24.



6. Mwakigonja AR, Pyakurel P, Kokhaei P, Pak F, Lema LK, Kaaya EE, et al. Human herpesvirus-8 (HHV-8) sero-detection and HIV association in Kaposi's sarcoma (KS), non-KS tumors and non-neoplastic conditions. *Infect Agent Cancer*. 2008;3:10.
7. Duc PH, Doan NV, Huy HQ. Unicentric Castleman's disease in the female pelvis. *Radiol Case Rep*. 2020;15(11):2221-4.
8. Wang YQ, Li SQ, Guo F. Video-assisted thoracoscopic surgery is a safe and effective method to treat intrathoracic unicentric Castleman's disease. *BMC Surg*. 2020;20(1):127.
9. Gill MK, Suri V, Dubey VK, Makkar M. Cytological diagnosis of Castleman's disease of the soft tissue. *J Cytol*. 2013;30(3):213-5.
10. Prakash G, Bal A, Malhotra P, Aggarwal V, Khadwal A, Suri V, et al. Presentation and Outcome of Castleman's Disease in Immunocompetent Hosts. *Indian J Hematol Blood Transfus*. 2016;32(4):468-74.
11. Kettani M, Touiheme N, Attifi H, Hmidi M, Boukhari A, Zalagh M, et al. Castle man disease: a case report and review of the literature. *Pan Afr Med J*. 2014;19:130.
12. Castleman B, Towne VW. Case records of the Massachusetts General Hospital; weekly clinicopathological exercises; founded by Richard C. Cabot. *N Engl J Med*. 1954;251(10):396-400.
13. Kubokawa I, Yachie A, Hayakawa A, Hirase S, Yamamoto N, Mori T, et al. The first report of adolescent TAFRO syndrome, a unique clinicopathologic variant of multicentric Castleman's disease. *BMC Pediatr*. 2014;14:139.
14. Tanaka T, Narazaki M, Kishimoto T. Therapeutic targeting of the interleukin-6 receptor. *Annu Rev Pharmacol Toxicol*. 2012;52:199-219.
15. Tanaka T, Narazaki M, Kishimoto T. IL-6 in inflammation, immunity, and disease. *Cold Spring Harb Perspect Biol*. 2014;6(10):a016295.