

Shoulder Dislocation in the course of Revenue Collection: A Need to Caution Revenue Agents in Port Harcourt

Type of Article: Case Report

Eyimina P. D., Echem R. C.

Department of Surgery, College of Health Sciences, University of Port Harcourt, Rivers State, Nigeria.

ABSTRACT

Background:

The shoulder joint exhibits great mobility and is the commonest major joint to be dislocated. Dislocation of the shoulder joint can result from falls, sports or trauma. We report a case of shoulder dislocation in the course of revenue collection.

Methods: The case records of a patient who sustained traumatic shoulder dislocation; following assault from revenue collection agents in Port Harcourt as well as a review of the literature on the subject was utilized.

Result: A 28-year-old right-hand dominant male presented with features of left anterior shoulder dislocation which he sustained in the course of preventing revenue agents gaining access into a room in his place of work. He had closed reduction of the shoulder with immobilization and post-immobilization physiotherapy. There has been no recurrence during the 15 months of follow-up so far.

Conclusion: Anterior shoulder dislocation can occur in the course of revenue collection if physical force is utilized. There is a need for revenue agents to avoid use of collection methods that will cause any form of musculoskeletal injury.

Keywords: Anterior; Shoulder dislocation; Violent Revenue collection

Correspondence: R.C. Echem

INTRODUCTION

The shoulder joint complex exhibits greater mobility than any other joint in the human body and this range of mobility is at the expense of stability^{1,2}. The glenohumeral joint is thus one of the most frequently dislocated joints and incidence rates of 8.2 to 23.9 per 100,000 person-years have been reported in the general population^{3,4}. Dislocations of the shoulder can be anterior, posterior or inferior but the commonest variety is the anterior dislocation which accounts for 96-98% of cases^{1,5}. Anterior dislocations are of four types which include the subcoracoid, subglenoid, subclavicular and intrathoracic types. Of these, the subcoracoid is the commonest^{6,7}.

Shoulder dislocations may result from a falls, sports or trauma. Anterior dislocations commonly occur when the arm is forced into a position of abduction, external rotation

and extension by a fall onto an outstretched arm or by direct force applied to the posterior aspect of the humeral head^{1,7,8}.

Revenue collection is required for the generation of revenue needed for the running of government and the provision of social and other services. Various State governments in Nigeria are formulating strategies to improve their revenue base⁹. These strategies include the utilization of tax consultant and revenue agents.

This paper aims to report a case of shoulder dislocation that occurred in the course of revenue collection and highlight the need to exercise caution to avoid musculoskeletal and other forms of injury which may result from the violent methods employed by state sponsored revenue agents and collectors.

CASE REPORT

A 28-year-old right-hand dominant male presented to a private clinic in Port Harcourt with a history of pain in the left shoulder of two hours duration. He was at his work site and while holding onto a door handle at the entrance of the site with his left hand, some revenue agents forcefully pulled him from the left side while he still held onto the handle in their bid to gain entrance into the room. He subsequently noticed pain in the left shoulder associated with difficulty in using the left upper limb. This was the first episode of such an incidence. He was not a known diabetic, asthmatic, hypertensive nor epileptic. He neither took alcohol nor smoked cigarettes.

Physical examination of the shoulder revealed that there was loss of shoulder contour with prominence in the anterior left shoulder. The arm was abducted and the left forearm was supported by the contralateral hand (Figure 1). There were no neurological deficits and the distal pulses were normal. There was no clinical evidence of generalized ligamentous laxity in the other joints. Other systems were essentially normal.

A plain radiograph of the left shoulder showed anterior dislocation of the glenohumeral joint with the humeral head in the subcoracoid position (Figures 2a and 2b). Under sedation with diazepam and pentazocine, the dislocation was reduced by a modification of the Hippocratic method utilizing folded bedsheets in the axilla for counter traction. Post reduction the shoulder contour was restored (Figure 3). The left shoulder was immobilized with crepe bandage and strap and post reduction plain radiographs confirmed reduction. The immobilization was for three weeks and this was followed by physiotherapy. He has been followed up for fifteen months with no recurrence

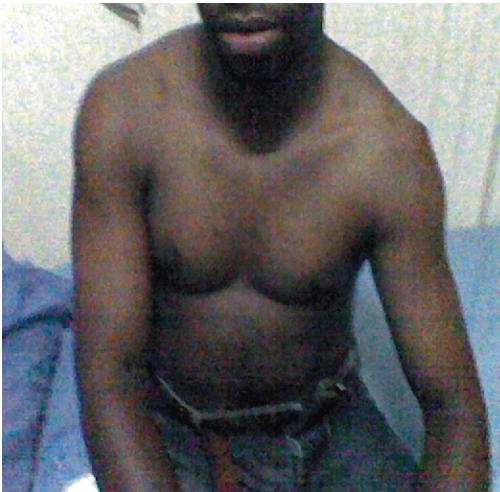


Figure 1 Clinical Photograph of the Patient showing left shoulder dislocation

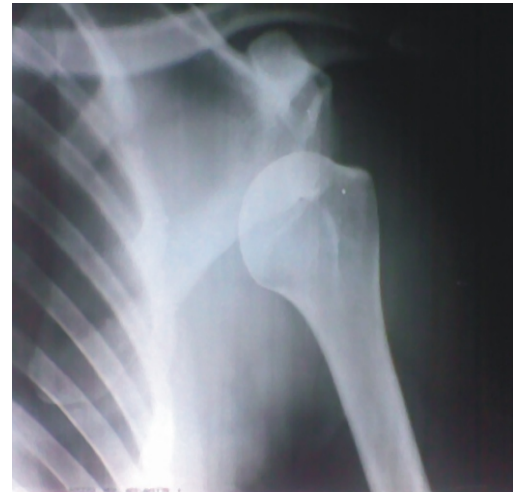

Figure 2b Plain Radiograph of the left shoulder showing anterior dislocation

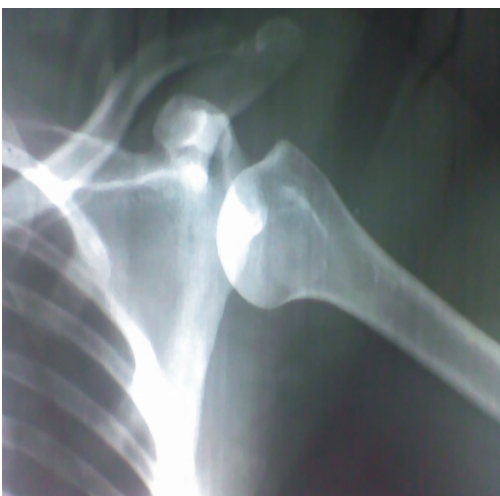

Figure 2a Plain Radiograph of the left shoulder showing anterior dislocation

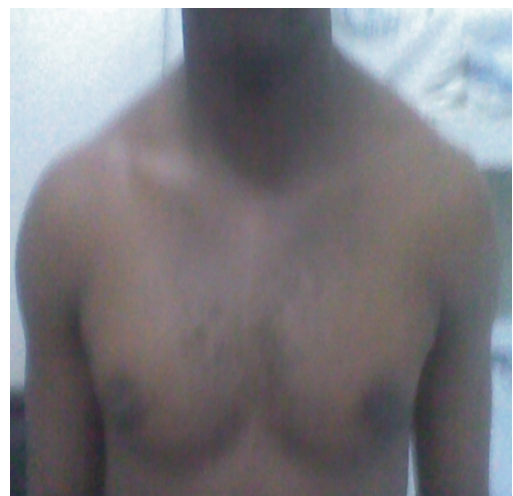

Figure 3 Clinical Photograph of the Patient after close reduction of the dislocation

of the shoulder dislocation.

DISCUSSION

Anterior shoulder dislocation can occur in the course of revenue collection if excessive force is exerted. Glenohumeral joint dislocation have been reported in young active males especially athletes^{1,3}. The dislocation may result from a fall onto an outstretched arm, during sporting activities and from trauma^{1,10}. A direct force to the posterior aspect of the shoulder can result in a dislocation^{1,2}. The usual mechanism of injury is an indirect levering of the humeral head anteriorly with the shoulder in some combination of abduction, extension and external rotation^{5, 6,7}. The index patient was a young man who was 28 years old and was attempting to prevent revenue agents from gaining entry into a room by holding firmly on to a door handle. In this position the shoulder is in abduction and extension. In order to move the patient from the door, the revenue agents would have attempted to force his hands off the handle by externally rotating the upper extremity and since he probably was resisting this, the left shoulder was put at risk of dislocation which subsequently occurred.

An association between joint laxity and joint injury has been reported⁴. Generalized ligamentous laxity predisposes to

primary traumatic anterior dislocation. This was the first episode of shoulder dislocation in the index patient and he did not show any evidence of ligamentous laxity. The patient did not have this obvious predisposition to shoulder dislocation.

Seizures and electric shock have been related to shoulder dislocations⁶, although this is noticed more with posterior dislocation than with anterior dislocation. The index patient did not have any history of prior seizures.

The clinical presentation of anterior shoulder dislocation is usually straight forward. The index patient presented with a history which was suggestive of a shoulder dislocation and physical examination revealed loss of the left shoulder contour and the arm in abduction and external rotation and the left forearm being supported by the contra lateral hand. These findings have been reported in the literature⁹.

Significant stress can be placed on the neurovascular structures that course through the axilla as well as on the rotator cuff, the glenoid rim, joint capsular, stabilizing ligaments and the humeral head by the dislocation mechanism and the dislocation itself. This results in complications. A number of complications have been

reported and include axillary artery injuries, brachial plexus and other isolated nerve injuries, rotator cuff injury, damage to glenohumeral ligaments, recurrence, bony injuries such as glenoid lesions (Bankart lesion), humeral lesions (Hill-Sachs's) and greater tuberosity fractures^{6,7,10}. Shoulder arthrosis following dislocation has also been reported¹¹. All these complications are possibilities in the index patient but none was noticed. Although recurrence have been reported commonly in those younger than 30 years with a reported rate of 17 to 96%⁸, the index patient has not presented with any recurrence in the fifteen months of follow up. Early arthroscopic lavage and stabilization have been advocated to reduce recurrence^{8,12}.

A plain radiograph usually confirms anterior shoulder dislocation. Anterior shoulder dislocation could be subcoracoid, subglenoid, subclavicular or intrathoracic^{6,7}. While the intrathoracic type is rare, the subcoracoid is the most common. The index patient had a subcoracoid anterior dislocation.

Several methods of shoulder reduction have been advocated. These methods have been classified into traction techniques (Hippocrates, Stimson, Spaso and Eskimos), leverage techniques (Kocher and Milch), scapular manipulation techniques, combinations (of the earlier techniques) and miscellaneous which include direct pressure and pulsion^{2,7,13}. Other "new" techniques such as FARES (Fast, Reliable and Safe) have also been advocated¹⁴. Many of the described methods of reduction are essentially modifications of previously employed methods. Although no single shoulder reduction technique is infallible, the method chosen should require minimum assistance, be highly effective, quick, safe and relatively painless¹⁴. A modification of the Hippocratic method utilizing folded bedsheets in the axilla for counter traction was utilized in the index patient.

Immobilization and rehabilitation are traditional treatments in shoulder dislocation^{1,5}. The period of immobilization varies from 3 to 6 weeks depending on the age of the patient, first time versus recurrence, traumatic versus atraumatic and associated injuries⁵. Immobilization should allow the pathological lesions to heal and the injured anterior tissues to "scar" in order to provide some resistance to excessive external rotation and prevent redislocation. Post immobilization rehabilitation to restore motion and strength is also recommended⁵. The index patient was immobilized for 3 weeks followed by physiotherapy.

Revenue generation is important for all levels of government to function properly. In as much as this is so, it is important that the method of revenue collection should avoid body injury. As can be seen in this patient, excessive force was required to cause the anterior shoulder dislocation. Although this patient did not have any of the common complications with shoulder dislocation so far, these are possibilities which could be avoided. In addition, time is lost from work as a result of the injury. This loss is avoidable. The revenue agents utilize unorthodox methods and these include harassment of tax payers with armed police and soldiers as well as physical abuse of the tax payers. More civil methods of revenue collection should be adopted and defaulters should be prosecuted in court after due notification rather

than the tax payer being physically abused.

CONCLUSION

Anterior shoulder dislocation can occur in the course of revenue collection if physical force is utilized. There is a need for revenue agents in Port Harcourt to avoid the use of collection methods that will cause any form of musculoskeletal injury.

REFERENCES

1. Karatsolis K, Athanasopoulos S. The role of exercise in the conservative management of the anterior shoulder dislocation. *J Body Mov Ther* 2006; 10:211-219.
2. Mattick A, Wyatt JP. From Hippocrates to the Eskimo - a history of techniques used to reduce anterior dislocation of the shoulder. *J R Coll Surg Edinb* 2000; 45:312-316.
3. Zacchilli MA, Owens BD. Epidemiology of shoulder dislocations presenting to emergency departments in the United States. *J Bone Joint Surg Am* 2010; 92:542-549.
4. Chahal J, Leiter J, McKee MD, Whelan DB. Generalized ligamentous laxity as a predisposing factor for primary traumatic anterior shoulder dislocation. *J Shoulder Elbow Surg* 2010 (Epub ahead of print).
5. Wen DY. Current concepts in the treatment of anterior shoulder dislocations. *Am J Emerg Med* 1999; 17:401-407.
6. Beeson MS. Complications of shoulder dislocation. *Am J Emerg Med* 1999; 17:288-295.
7. Cunningham NJ. Techniques for reduction of anteroinferior shoulder dislocation. *Emerg Med Australas* 2005; 17:463-471.
8. Kirkley A, Griffin S, Richards C, Miniaci A, Mohtadi N. Prospective randomized clinical trial comparing the effectiveness of immediate arthroscopic stabilization versus immobilization and rehabilitation in first traumatic anterior dislocations of the shoulder. *Arthroscopy* 1999; 15:507-514.
9. Kiabel BD, Nwokah NG. Boosting revenue generation by state governments in Nigeria: the tax consultant's option revisited. *European Journal of Social Sciences* 2009; 8:532-539.
10. Kosiyatrakul A, Jitprapaikularn S, Durand S, Oberlin C. Recovery of brachial plexus injuries after shoulder dislocation. *Injury* 2009; 40:1327-1329.
11. Marx RG, McCarty EC, Montemurno D, Altchek DW, Craig EV, Warren RF. Development of arthrosis following dislocation of the shoulder: a case-control study. *J Shoulder Elbow Surg* 2002; 11:1-5.
12. Davy AR, Drew SJ. Management of shoulder dislocation - are we doing enough to reduce the risk of recurrence? *Injury* 2002; 33:775-779.
13. Chung CH. Closed reduction techniques for acute anterior shoulder dislocation: from Egyptians to Australians. *Hong Kong J Emerg Med* 2004; 11:178-188.
14. Sayegh FE, Kenanidis EI, Papavasiliou KA, Potoupnis ME, Kirkos JM, Kapetanios GA. Reduction of acute anterior dislocations: a prospective randomized study comparing a new technique with the Hippocratic and Kocher methods. *J Bone Joint Surg Am* 2009; 91:2775-2782.