



Mammographic Findings among Women in Port Harcourt: a Multicentre Study

¹Onwuchekwa Chinwe R, ²Alazigha Nengi S

Department of Radiology, Faculty of Clinical sciences, College of Health Sciences, University of Port Harcourt¹;

Department of Radiology, Braithwaite Memorial Specialist Hospital, Port Harcourt²

Correspondence: Email: chichekwas2003@yahoo.com

ABSTRACT

Background: Mammography is the primary imaging modality for breast diseases evaluation, cancer screening and diagnosis. The increasing incidence of breast cancer worldwide has made mammography an important tool; as mammography breast cancer screening had shown to reduce mortality. The aim of the study is to evaluate the indication for mammography referral and the prevalence of breast lesions in our locality with a view to assessing the benefits of mammography practice in our health facility

Methods: This was a prospective descriptive study of all mammogram performed during the five years of the study. Information on patient's age, parity, last menstrual period, breast feeding, occupation, indication for mammogram referral and past mammographic exposure were entered into excel spread sheet as they were collected.

Results: The patients' age ranged from 22 to 78 years with a mean of 48.34 ± 1.04 years. The

commonest indication for mammography were breast screening for cancer which constituted 97(36.60) patients, followed by breast lump constituting 74(27.94%) patients and breast pain in 56(21.13%) patients. Evaluation of the mammographic findings showed that 158 (59.62%) patients had normal findings. The BI-RADS category showed high prevalence of category 1 which was found in 155 (58.49%) patients

Conclusion: The study had shown that mammography is an important imaging modality for evaluating breast lesions. Breast screening mammography had become acceptable to women in our society, especially if the financial implication is not burdensome on them. It was also demonstrated that benign breast lesions were commoner than malignant lesions, hence giving hope to patients who were scared of the outcome of their mammogram.

Key words: Breast cancer, breast screening, mammography, mortality, morbidity, indications.

INTRODUCTION

The breast is located on the anterior thoracic wall. It extends horizontally from the lateral border of the sternum to the mid-axillary

line; vertically spanning between the 2nd and 6th intercostal cartilages. It lies superficially to the pectoralis major and serratus anterior muscles. The breast is composed of





mammary glands surrounded by a connective tissue stroma. Each gland consists of duct and secretory lobules which ranges from 15-20.¹ Each lobule consists of many alveoli drained by a single lactiferous duct that converges at the nipple. The connective tissue stroma consists of fibrous and fatty components as well as blood vessels, nerves and lymphatics. The proportion of these structures in the breast determines its size and density on mammogram.² Mammography uses low energy x-ray of about 30kVp for imaging and produces greater contrast between the various structures that make up the breast. It is the primary imaging modality for breast diseases evaluation, cancer screening and diagnosis.

Both ultrasound and magnetic resonance imaging are important complimentary modalities to x-ray mammography for diagnosing, characterizing and determining the extent of breast lesions. While ultrasound is routinely utilized in these roles, the routine use of MRI is still limited by local logistics and availability.³

Breast cancer is the most common cause of cancer deaths among women worldwide^{4,5} and the second most common cause of death due to cancer among Nigerian women.^{6,7} The increasing incidence of breast cancer worldwide has made mammography an important tool as it had been shown that mammography breast cancer screening reduces mortality.⁸ It is capable of detecting cancer at very early stage when it is treatable and this had helped in reducing mortality and morbidity in part of the world with organized screening programs for breast cancer. In Nigeria breast cancer screening is not yet

satisfactory as no organized program is in place for it and most of the patients still present with advanced breast cancer.

Auditing the mammography services in our locality will show the pattern of presentation of the breast diseases and enable advocacy in proper breast cancer screening program. The aim of the study is to evaluate the indication for mammography referral and the prevalence of breast lesions in our locality with a view to assessing the benefits of mammography practice within a five-year period.

MATERIALS AND METHODS

This was a prospective descriptive study of all mammogram performed in the radiology department of a Government Specialist Hospital and a Specialist Private Hospital in the city of Port Harcourt, Rivers state. The study lasted for five years, from January 2012 to December 2016. The information on patient's age, parity, last menstrual period, breast feeding, occupation, indication for mammogram referral and past mammographic exposure were entered into excel spread sheet as they were collected. Two standard views were taken for each breast, cranio-caudal (CC) and medio-lateral oblique (MLO) views; and additional views such as spot compression magnification view, cleavage view and exaggerated CC views were taken where necessary.

The mammography machines used were METALTRONIC SRL. Manufactured by Via Della Pisana, 431-00163 Rome, Italy at the Specialist Private Clinic and General Electric (GE) Senographe DMR machine at the Government Specialist Hospital.



All the patients had their mammograms reviewed by a radiologist before leaving the department.

The mammographic findings were classified as benign or malignant according to the Breast Imaging Reporting and Data System (BI-RADS) designed by the American College of Radiology (ACR) in 1992 to standardize reporting [9]. For the purpose of this study, BI-RAD categories 1 is considered negative finding, BI-RADS 2, & 3 were assigned benign finding while BI-RADS categories 4 & 5 were assigned malignant findings. BI- RADS 0 was assigned inconclusive and requires further evaluation.

The ethical standard laid down in the declaration of Helsinki was applied in all data collection and all the patients used in the study provided informed consent. The protocol was approved by the institutional review board at each hospital.

The collected data was analysed using SPSS version 20. Frequency tables and text were used to present the results.

RESULT

The patients' age ranged from 22 to 78 years with a mean of 48.34 ± 1.04 year. Most of the patients were between 41 and 50 years (46.4%), shown in Table 1.

Table 1: Age distribution of patients

Age	Number	Percentage %
21-30	7	2.6
31-40	49	18.5
41-50	123	46.4
51-60	50	18.9
>60	36	13.6
Total	265	100

One hundred and fifty-eight (59.6%) were premenopausal while one hundred and seven (40.4%) were postmenopausal. Only 7(2.64%) had previous mammogram. 4(1.51%) had lumpectomy in the past, and two (0.75%) have had unilateral mastectomy. The commonest indication (Table 2) for mammography were breast screening for cancer which constituted 97(36.60%) patients, breast lump constituting 74(27.94%) patients and breast pain in 56(21.13%) patients.

Table 2: Indication for the mammogram

Indication	Frequency	Percentage %
Screening	97	36.60
Breast lump	74	27.94
Breast pain	56	21.13
Mastitis	15	5.66
Cyst	8	3.02
Discharge	6	2.26
Breast swelling	3	1.13
Arm swelling	2	0.75
Nipple ulcer	2	0.75
Axillary lymph nodes	1	0.38
Duct ectasia	1	0.38
Total	265	100

Evaluation of the mammographic findings (Table 3) showed that 158 (59.62%) patients had normal findings.

Table 3: Mammography findings.

Findings	Number of patients	Percentage %
Normal	158	59.62
Masses	81	30.57
Dense breast	11	4.15
Calcifications	8	3.02
Lymph nodes	3	1.13
Scar	2	0.75
Mondor disease	2	0.75
Duct ectasia	1	0.38

Of the patients with lesions in the breast, 81(30.57%) patients had breast masses which included cysts, fibroadenoma, intramammary lymph nodes or cancers (Fig 1, 2 &3) which may or may not be associated with calcifications (Fig 4).

Figure 2: cranio- caudal (CC) view mammogram of the right breast showed a benign well- defined dense mass with smooth margin and no architectural distortion.

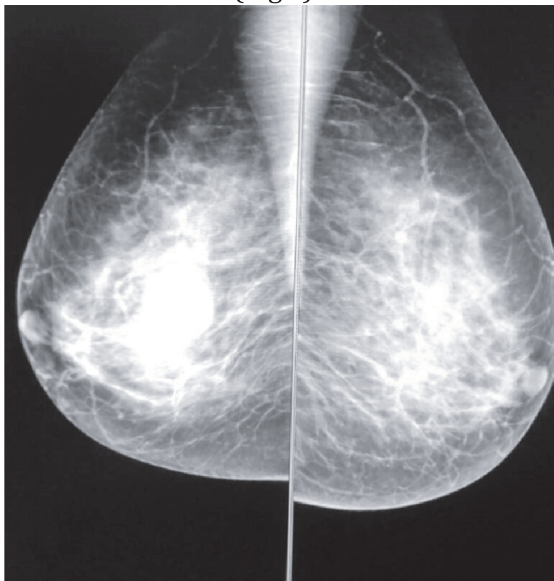


Figure 1: A mediolateral oblique view mammogram of both breasts showing an ill-defined dense right breast malignant mass with mild architectural distortion.

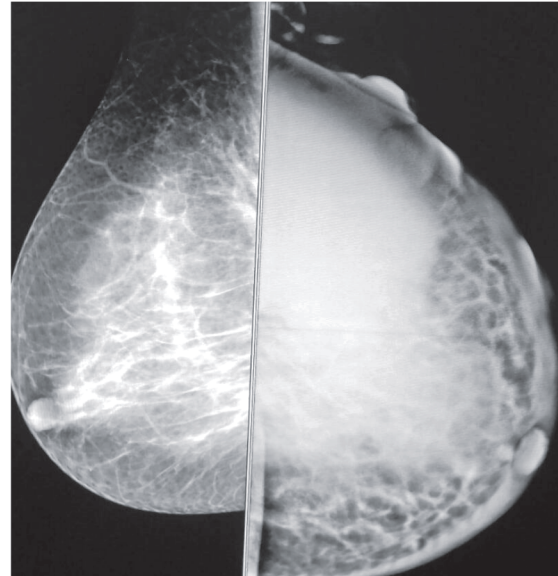


Figure 3: Mediolateral oblique (MLO) view mammogram of the breast showed a large malignant dense left breast mass with ulceration, skin thickening (arrow) and nipple retraction (arrow head). The right breast is normal.

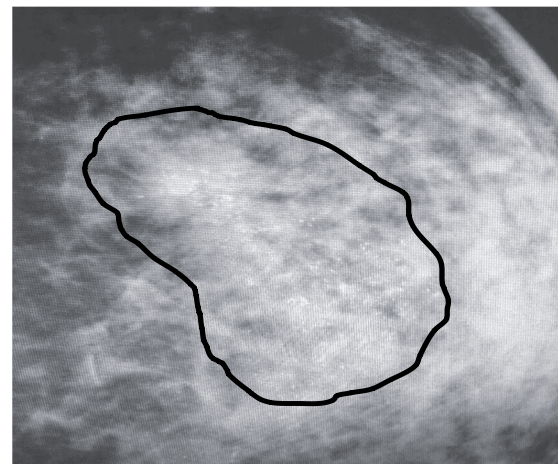
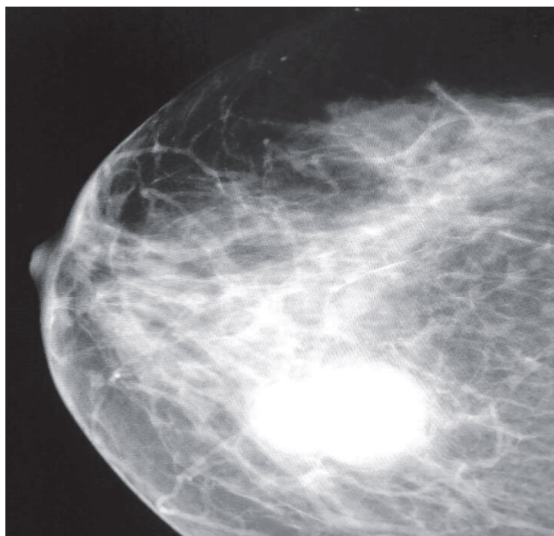


Figure 4: Magnification view of the breast showing area of pleomorphic calcification in the breast

The BI-RADS category as demonstrated in Table 4 showed high prevalence of category 1 which was found in 155 (58.49%) patients.

Table 4: Mammography findings.

BI-RADS	Number of patients	Percentage %
0	2	0.75
1	155	58.49
2	37	13.96
3	30	11.32
4	36	13.58
5	5	1.89

DISCUSSION

Mammography has proved to be an effective method for evaluating breast diseases especially cancer diagnosis. It is capable of detecting small lesions even before a lump is felt. Breast cancer screening using mammography starts after the age of 40 years which is the period of peak incidence of the breast cancer. The American cancer society and the American College of Radiology recommended yearly mammogram beginning at the age of 40 years.¹⁰

This audit study showed that the largest number of the patients seen, were between the ages of 41 to 50 years which constituted 46.4%. The mean age was 48.34 years which is within the peak age range. Similar observation had been made in similar studies carried out in the Western part of our country.¹¹⁻¹³ Contrary to these reports were two previous studies which evaluated

symptomatic patients and they got a peak age of incidence and mean age of below 40 years.^{14,15} This difference could be explained by the fact that majority of our patients were for breast cancer screening which constituted 36% of the study population; most of whom were oil company staff that came for annual medical examination which included mammography for the females. There were more premenopausal women (59.6%) than postmenopausal women (40.4%) in this study which is similar to what had been reported previously in literatures.^{16,17} Breast lesions in premenopausal women are more commonly benign especially those occurring during pregnancy and child birth; this could have accounted for the high rate of this group of women in this study.

Breast lumps accounted for the highest clinical indication for those that presented with symptoms and this was closely followed by breast pain. Previous studies in Nigeria^{11,13,15,18} and United States⁹ had shown that the commonest indication for mammography was breast lump. This is understandable as most breast cancers present with breast mass, and palpation of mass in the breast instils fears into the patients which strengthen their resolve to have the mammography done. In the index study, 59.62% of the patients were found to have no breast lesion. This was in contrast to what was reported in previous studies, which recorded more breast lesions.^{11,19,20} Abnormalities were found in 40.38% of the study population; and of these, the commonest finding were mass lesions which were seen as opacities of various patterns. Majority were reported as benign. This was in accordance with the findings in previous



researches which showed that benign breast lesions were commoner than malignant lesions [3,11,21]. BI-RADS 1 was the most prevalent in this study, followed by BI-RADS 2; this may be a consequence of the large number of screening mammography referral in this study population. In previous studies with similar population stratification, high incidence of benign breast lesions was reported in those with breast lesion.^{3,11,21,22}

CONCLUSION

The study had shown that mammography is an important imaging modality for evaluating breast lesions and for cancer screening in order to detect breast cancer early at a time treatment would be beneficial. Breast screening mammography had become acceptable by women in our society especially if the financial implication is not burdensome on them as demonstrated by large number of breast screening mammogram from the company staff. It was also demonstrated that benign breast lesions were more common than malignant lesions, hence giving hope to patients who are scared of the outcome of their mammogram.

REFERENCES

1. Harold E, Vishy M. Clinical anatomy: Applied anatomy for students and junior doctors. Wiley- Blackwell, John Wiley & Sons Ltd publication UK. 12th edition. 2010; 207-211.
2. Heng D, Gao F, Jong R, Fishell E, Yaffe M, Martin L, et al. Risk factors for breast cancer associated with mammographic features in Singaporean Chinese women. *Cancer Epi Biom Prev.* 2004; 13: 1751-8.
3. Starvos AT, Thickman D, Rapp U, et al. Solid breast nodules: use of sonography to distinguish between benign and malignant lesion. *Radiology.* 1995; 196: 123-134.
4. Douglas S. Should we screen women with mammography in Hong Kong? *The Hong Kong Practitioner* 1994; 16(9): 447-56.
5. Hardy JD, Kukora JS, Harvey IP. Cancer of the breast, epidemiology and aetiology. Hardy's text book of surgery, JB Lippincott Company Philadelphia, second edition. 1988.
6. Out AA, Ekanem OO, Khalil ML, Attah EB, Ekpo MD. Characterisation of breast cancer subgroup in an African population. *British journal of Surg* 1989; 71: 182-4
7. Okobia MN, Aligbe JU. Pattern of malignant diseases at the University of Benin Teaching Hospital. *Trop Doct* 2005; 35: 91-2.
8. Tabar L, Vitak B, Chen HH, Prevost TC, Duffy SW. Update of the Swedish two-county trial of breast cancer screening: histological grade-specific and age specific results. *Swiss Surg* 1999; 5(5): 199-204.
9. Berta MG, William EB, Rachel BB, Virginia LE, Bonnie CY, Edward AS et al. Use of the American college of radiology BI-RADS to report on the mammographic evaluation of women with signs and symptoms of breast disease. *Radiology* 2002; 222: 536-542.
10. American Cancer Society. Breast cancer facts and figures 2005-2006. Atlanta. American Cancer Society; Inc.; 2005.
11. Akande HJ, Olafimihan BB, Oyinloye OI. A five-year audit of mammography in a tertiary hospital, North Central Nigeria. *Nigerian Medical Journal* 2015; 56(3): 213-17.



12. Obajimi MO, Adeniji-Sofoluwe AT, Oluwasola AO, Adedokun BO, Soyemi TO, Olopade F et al. Mammographic breast pattern in Nigerian women in Ibadan, Nigeria. *Breast Dis.* 2011; 33: 9-15.
13. Akinola RA, Akinola OL, Shittu L, Balogun BO, Tayo AO. Appraisal of mammography in Nigeria women in a new teaching hospital. *Scientific Research and Essay* 2007; 2(8): 325-9.
14. Ademyomoye AAO, Awosanya GOG, Adesanya AA, Anunobi CC, Osibogun A. Medical audit of diagnostic mammographic examination at the Lagos University Teaching Hospital (LUTH), Nigeria. *Niger Postgrad Med J.* 2009; 16(1): 25-30.
15. Eni UE, Ekwedigwe KC, Sunday- Adeoye I, Daniyan ABC, Isikhuemen ME. Audit of mammography requests in Abakaliki, South-East Nigeria. *World Journal of Surgical Oncology.* 2017; 15: 56. Doi 10.1186/s12957-017-1122-7.
16. Nggad HA, Gali BM, Bakari AA, Tema EH, Tahir MB Apari E, et al. The spectrum of female breast diseases among Nigerian population in Sahel climate zone, *J med sci* 2011; 2: 115-61.
17. Anele AA, Okoro IO, Oparaocha DC, Igwe PO. Pattern of breast diseases in Owerri, Imo state, Nigeria. *PHMJ.* 2009; 4 (1): 84-87.
18. Ayoade BA, Tade AO, Salami BA. Clinical features and pattern of presentation of breast diseases in surgical outpatient clinic of a suburban tertiary hospital in South-west Nigeria. *Niger J Surg.* 2012; 18:13-6.
19. Okere P, Aderigbibe A, Iloanusi N, Olusina DB, Itanyi D, Okoye I. An audit of the first three years of mammography and sono-mammography at the University of Nigeria Teaching Hospital, Enugu, Nigeria. *J Coll Med* 2012; 17: 2.
20. Ebubedike UR, Umeh EC, Anyanwu SNC, Ukah CO, Ikegwuonu NC. Pattern of mammography findings among symptomatic females referred for diagnostic mammography at a tertiary center in South-East Nigeria. *West African Journal of Radiology* 2016; 23(1): 23-7.
21. Ochicha O, Edino ST, Mohammed AZ, Amin SN. Benign breast lesions in Kano, *Nig J Surg Res.* 2002; 24: 257-62.
22. Ikpeme A, Akintomide A, Inah G, Oku A. Breast evaluation findings in Calabar, Nigeria. *Macedonian Journal of Medical Sciences* 2014; 4(2). Doi 10.3889/oamjms.2014.117.