

A Case of Meningioma Presenting as Stroke

Type of Article: Case Report

Sotonye Dodiya-Manuel, Tochukwu Ilodibia

Department of Internal Medicine, University of Port Harcourt Teaching Hospital, Port Harcourt, Nigeria.

ABSTRACT

BACKGROUND

Meningioma is a common intracranial tumor that accounts for 14 to 19% of all primary intracranial neoplasms. Over 90% are benign and confirmed by either histology or radiological studies. We report a case of meningioma mimicking a stroke with adult onset tonic clonic seizures.

METHODS

The case records of a 47-year-old female at the University of Port Harcourt Teaching Hospital and a review of the literature utilizing Google and Pub Med search was utilized.

RESULT

A 47 year old housewife presented to the emergency room with a 17 hour history of repeated generalized seizures and a 6 hour history of left sided limb weakness. She had a 10-year history of recurrent adult onset seizures and had a transient ischaemic attack 2 years prior to p r e s e n t a t i o n . A clinical diagnosis of right hemispheric stroke with left hemiparesis and left facial nerve palsy was made. A brain computerized tomography (CT) scan revealed a meningioma and the patient was referred for surgery.

CONCLUSION

Strokes in developing countries like ours are sometimes managed without

radiological evaluation due to financial constraints. There is however, the possibility of missing out treatable causes and stroke mimics like meningioma. Stroke misdiagnosis due to meningioma is a rare clinical occurrence but the presence of adult onset seizures should raise the suspicion and prompt further evaluation.

KEYWORDS

Meningiomas; Stroke Mimic; Seizures

*Correspondence: Dr S.T. Dodiya-Manuel
Email: tbtsspecial@yahoo.com*

INTRODUCTION

Meningioma is a common intracranial tumor that accounts for 14 to 19% of all primary intracranial neoplasms¹. Meningiomas frequently originate in the suprasellar, frontobasal, temporobasal, sphenoid wing or petroclival regions². Tumors situated in these locations often involve an intracranial portion of the internal carotid artery (ICA) and may compromise cerebral blood flow³. Over 90% of meningiomas are benign and confirmed by either histology or radiological studies⁴. Whether histologically benign or not, meningiomas are of importance to clinicians because of their established role as stroke mimics.

Computerized tomography (CT) scans are central to the triage of suspected cases of stroke as they enable the confirmation of stroke, differentiation of stroke sub-types, and

the exclusion of infections and extra-axial lesions (such as meningiomas) which can mimic strokes⁵. Sole reliance on clinical evaluation results in significant rates of stroke misdiagnosis ranging from 7.5% following clinical audit⁶, to as high as 25.1%⁵ and 34.5%⁷ when these clinical diagnoses were subjected to CT confirmation. The latter two local studies revealed stroke mimic frequencies of 13.3%⁵ and 23.2%⁷ respectively. Since many of these stroke mimics are amenable to definitive surgical intervention, the place of neuro-imaging in this clinical context cannot be over-emphasized⁸.

We report a case of meningioma presenting with tonic-clonic seizures and mimicking a hemorrhagic stroke.

CASE SUMMARY/REPORT

A 47 year old housewife, presented to the Emergency Room with a 17 hour history of repeated generalized limb seizures and a 6 hour history of left sided limb weakness. Seizures began in the left limbs with subsequent involvement of the right limbs without an aura. The left leg was weaker than the left arm and the patient was right-handed.

There was a positive history of generalized throbbing headache and slurring of speech but no history of vomiting or loss of consciousness. A history of diplopia, dizziness or dysphagia was absent. There was no history of fever, neck pain, photophobia and head or neck trauma. She did not drink alcoholic beverages or use tobacco products or recreational drugs in any form.

She was a known hypertensive with poor adherence to treatment and had experienced sudden onset weakness of the left limbs two years previously with apparent full recovery within 24 hours. She also had a history of occasional focal seizures involving the left limbs over the preceding ten years but had never been placed on regular anticonvulsant therapy. The patient had a positive family history of diabetes mellitus and systemic hypertension but no history of seizure

disorder.

On examination, she was class 2 obese (BMI=38.7kg per sq meter) and conscious with a left facial nerve palsy (upper motor neuron type) and hypotonia in the left limbs. Power was grade 2 in the left arm and grade zero in the left leg, while deep tendon reflexes were depressed in both left limbs. Plantar response was extensor on the left and flexor on the right while sensation was intact. There were no abnormalities in the right limbs at presentation.

Blood pressure (BP) on admission was 200/130 mmHg (MAP=153.3 mmHg). The apex beat was felt in the 5th left intercostal space lateral to the mid-clavicular line. A fourth heart sound was heard. No murmur or vascular bruit was elicited.

The immediate working clinical diagnosis was a right hemispheric stroke (probably hemorrhagic) with left hemiparesis and left facial palsy, with background hypertensive heart disease. The other clinical differential diagnoses were Todd's paralysis following status epilepticus in a known seizure disorder patient, and an intracranial space-occupying lesion.

An urgent brain CT scan was requested while the patient was commenced on our standard stroke regimen of intravenous mannitol and frusemide for reduction of intracranial pressure, oral carbamazepine, amlodipine and intravenous normal saline.

The patient's CT scan axial slices (Figure 1) showed a large, sharply demarcated, hyperdense, homogeneous and mildly enhancing mass on the right, measuring 81 x 58 mm (HU=40.5), originating from the under-surface of the right fronto-parietal bone and extending down to the sphenoid with areas of extensive curvilinear calcification (with necrotic areas within). The mass crossed the midline with extensive peri-lesional edema and effacement of the adjacent sulci, gyri and the ipsilateral lateral ventricle. The

contralateral lateral ventricle was also dilated while the bone windows showed intact cranium with a normal cranial vault and sella. A radiologic diagnosis of meningioma was made in line with current radiographic criteria, which has been found to be reliable⁹. Intravenous dexamethasone and oral ramipril-hydrochlorothiazide were added to the regimen and physiotherapy commenced. The patient achieved good seizure control and facial and limb paresis significantly improved. She was subsequently referred to a specialist neurosurgical facility outside the state for definitive treatment. She was, unfortunately, lost to follow-up thereafter.

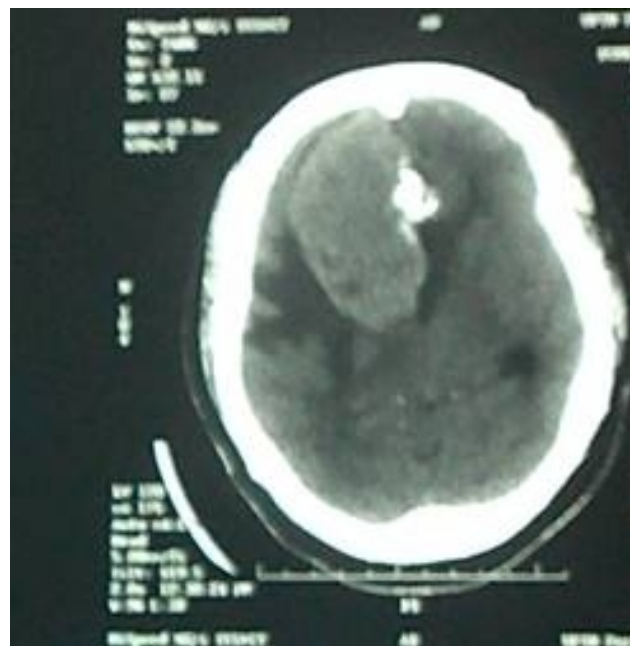
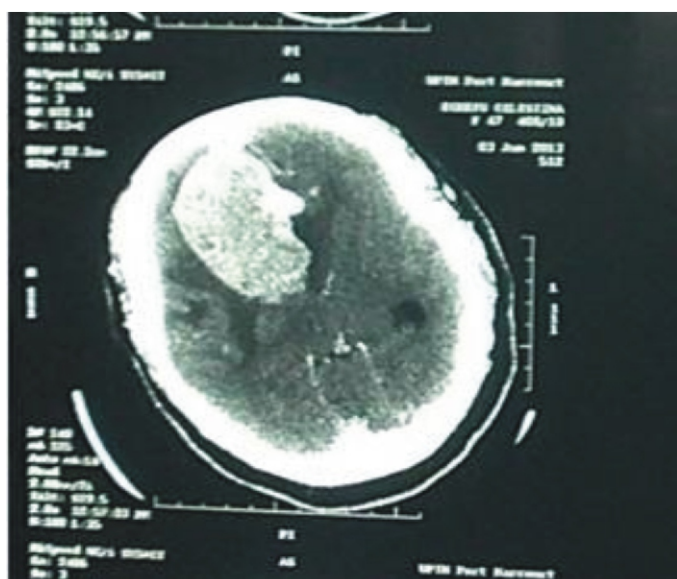
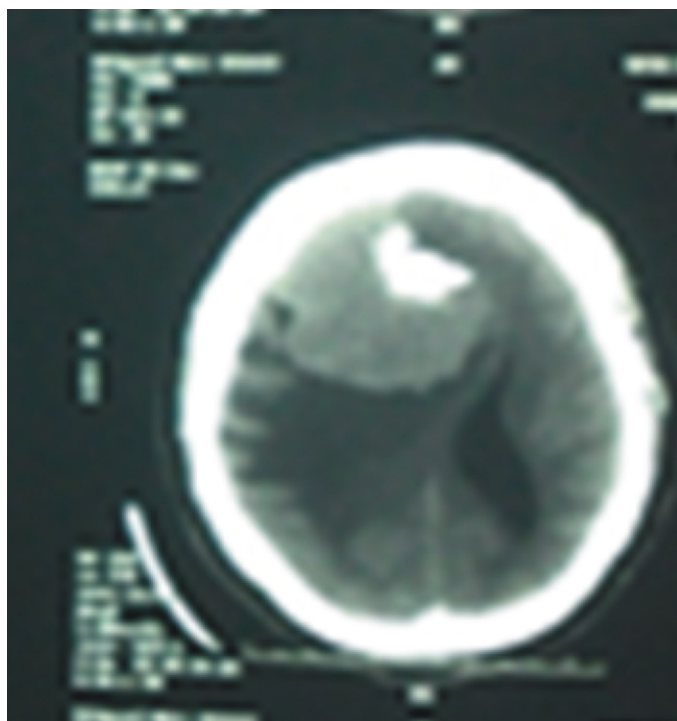


Figure 1. CT Scan showing a large well-demarcated hyperdense mass arising from the right fronto-parietal bone and containing an area of curvilinear calcification.



DISCUSSION

There are several sub types of meningioma, which may be meningotheiomas, fibrous or psammomatous. Their identification however has little prognostic value¹⁰. As illustrated by this case report and a previous local report of a patient with a 12-year history of Jacksonian epilepsy¹¹, meningiomas can cause adult onset seizures. Meningiomas may present with seizures, acute focal limb weakness and severe hypertension and may mimic stroke.

Histologic features are used to classify meningiomas into one of the three World Health Organization (WHO) grades which are useful in predicting recurrence and survival rate. About 90% of tumors are grade 1 (benign) with a risk of recurrence after post-surgical resection of 7- 20%. Incidence of grade II meningiomas (atypical) is 5- 7% with a recurrence rate of 40% whereas less than 3% are classified as grade III (malignant or anaplastic)⁶. Between 50- 80% of malignant cases will recur^{1 2}. Several risk factors for the development of meningioma have been postulated, though no clear association is identified. Ionizing radiation is currently acknowledged as the

leading cause of meningioma¹³. Others include low levels of physical activity, history of oophorectomy, high body mass index (BMI) in the years preceding diagnosis, history of uterine fibroids, history of first degree family members diagnosed at a young age and female related hormones^{14,15}. A low level of physical activity and high body mass index were found in our patient.

Although meningioma commonly involves the internal carotid artery (ICA), they rarely present with stroke¹⁶. In most of these cases, the different manifestations constitute a transient neurological deficit mimicking transient ischaemic attacks (TIA) probably due to haemodynamic stenosis. Our patient also had a history of TIA two years prior to presentation. It has been suggested that compression of the carotid artery by meningioma may produce transient neurological symptoms including loss of consciousness, hemiparesis, paresthesia and global transient amnesia¹⁶. However, complete cerebral infarction due to meningioma is exceedingly rare and only few cases have been reported in the literature^{17,18}. The incidence of meningioma related cerebral ischaemia by carotid artery compression is estimated at only 0.13%¹⁶. The reason why strokes are infrequent in this situation is still unknown but it has been hypothesized that arteries (with high pressure) may be less compromised than cortical veins and dural sinuses (with low pressure)¹⁶.

On computerized tomography (CT) scan, meningiomas are well defined extra axial masses which displace adjacent brain. Most are iso to hyperdense compared with normal brain, and there is strong uniform enhancement after intravenous contrast^{19,20}. There is usually perilesional oedema while calcifications and hyperostosis may be evident²⁰. Magnetic resonance image (MRI) may show hypo to isointense signal lesions on T1- weighted imaging and iso to hyperintense on T2- weighted imaging with a strong homogenous enhancement post gadolinium^{19,20}. Most meningiomas show a characteristic

dural thickening that taper peripherally (dural tail sign) accurately localizing the tumor to dural or sub dural space. Angiography has a major role to play in assessing highly vascular tumors pre operatively or tumors that are adjacent to venous sinuses that may be involving the sinuses.

While MRI is the imaging modality of choice for suspected meningioma, many meningiomas are initially detected on brain CT in real-world practice such as the triage of suspected stroke cases especially in resource-constrained settings²¹. CT also better demonstrates the effects of the tumor on adjacent bone, shows greater sensitivity in the detection of psammomatous calcification, and can be used in certain scenarios (e.g. pacemaker dependent patients) where MRI is contraindicated²¹.

It is generally recommended that small tumors, that are stable in size over time and asymptomatic, should be monitored through serial imaging. However, in patients less than 65 years of age like our patient, surgery is recommended. Curative treatment of meningiomas can be achieved by surgery alone when the tumor, its dural attachment and infiltrated bone can be completely excised¹⁰. Radiation therapy is indicated when gross total resection cannot be achieved, when tumors recur after surgery and in radiographically diagnosed tumor when biopsy is not possible. It also provides adjuvant therapy following resection of atypical and malignant meningiomas¹³. The role of chemotherapy is limited to treatment of tumors that recur after surgery or when radiotherapy options are exhausted¹⁸.

CONCLUSION

Stroke in developing countries like ours, is sometimes managed without radiological evaluation due to financial constraints. There is, however, the possibility of missing out treatable causes/stroke mimics like meningioma. Strokes due to meningioma are a rare clinical occurrence but the presence of

adult onset seizures is an indication for further evaluation.

REFERENCES

1. Wara WM, Sheline GE, Newman H, Townsend JJ, Boldrey EB. Radiation therapy of meningiomas. *AJR* 1975; 123: 453-458.
2. Bitzer M, Topka H, Morgalla M, Friese S, Wockel L, Voigt K. Tumor-related venous obstruction and development of peritumoral brain oedema in meningiomas. *Neurosurgery* 1998; 42: 730-737.
3. Ishikawa M, Nishi S, Aoki T, Takase T, Wada E, Oowaki H, Katsuki T, Fukuda H. Predictability of Internal Carotid Artery (ICA) dissectability in cases showing ICA involvement in parasellar meningioma. *J Clin Neurosci* 2001; 8: 22-25.
4. Dolecek TA, Propp JM, Strong NE, Kruchko C. CBTRUS statistical report: primary brain and central nervous system tumors diagnosed in the United States in 2005-2009. *Neuro Oncol* 2012; 14: 1-49.
5. Onubiyi CCB, Nwankwo NC, Onwuchekwa RC, Ray-Offor OD, Eweputanna LI. Computerized tomography and clinical correlation of stroke diagnosis in University of Port Harcourt Teaching Hospital. *Journal of Medicine and Medical Sciences* 2015; 6:90-94.
6. Imam I, Olorunfemi G. Clinical diagnosis of stroke: Need for audit. *Annals of African Medicine* 2004; 3:167-169.
7. Onwuekwe IO, Ezeala-Adikaibe BA, Ohaegbulam SC, Chikani MC, Amuta J, Uloh HN. Stroke-mimics – A study of CT images in African stroke patients, *Journal of Neurological Sciences (Turkish)* 2008; 25:148-154.
8. Ogun SA, Oluwole O, Ogunseyinde AO, Fatade B, Odusote KA. Misdiagnosis of stroke- a computerized tomography scan study. *West Afr J Med* 2000; 19: 19-22.
9. Mezue MC, Ohaegbulam SC, Ndubuisi CA, Chikani MC, Achebe DS. Management of intracranial meningiomas in Enugu, Nigeria. *Surg Neurol Int* 2012; 3:110.
10. Marchand A, O'Shaughnessy J. Subtle clinical signs of a meningioma in an adult: a case report. *Chiropractic and Manual Therapies* 2014; 22: 8.
11. Ohaegbulam SC, Saddeqi N, Ikerionwu S. Intracranial tumors in Enugu, Nigeria. *Cancer* 1980; 46:2322-2324.
12. Norden AD, Drappatz J, Wen PY. Advances in meningioma therapy. *Curr Neuro Neurosci Rep* 2009; 9: 231-240.
13. Adappa ND, Lee JY, Chiu AG, Palmer JN. Olfactory groove meningioma. *Otolaryngol Clin North Am* 2011; 44: 965-980.
14. Johnson DR, Olson JE, Vierkant RA, Hammack JE, Wang AH, Folsom AR, Virnig BA, Cerhan JR. Risk factors for meningioma in post menopausal women: results from the Iowa Women's Health Study. *New Oncol* 2011; 13: 1011-1019.
15. Claus EB, Calvocoressi L, Bondy ML, Schildkraut JM, Wiemels JL, Wrensch M. Family and personal medical history and risk of meningioma. *J Neurosurg* 2011; 115: 1072-1077.
16. Komotar RJ, Kerwani SC, Wityk RJ. Meningioma presenting as stroke: report of two cases and estimation of incidence. *J Neurol Neurosurg Psychiatry* 2003; 74: 136-137.
17. Heye S, Maleux J, Van Loon J, Wilms G. Symptomatic stenosis of the cavernous portion of the ICA due to irresectable medial wing meningioma: treatment by endovascular stent placement. *Am J of Neuroradiology* 2006; 27: 1532-1534.
18. Masuoka J, Yoshioka F, Ohgushi H, Kurashima M, Matsushima T. Meningioma manifesting as cerebral infarction. *Neurologia Medico- Chirurgica* 2010; 50: 585-587.
19. Granger A, Sainbury R, Wilkinson T, Macfarlane M. Multiple meningiomas: case report and review of the literature. *J Clin Neurosci* 2000; 7: 222-228.
20. Gruber T, Dare AO, Balos LL, Lele S, Fenstermaker RA. Multiple meningiomas arising during long term therapy with progesterone agonist megestrol acetate. *J Neurosurg* 2004; 100: 328-331.
21. Saloner D, Uzelac A, Hetts S, Martin A, Dillon W. Modern meningioma imaging techniques. *J Neurooncol* 2010; 99:333-340.