

Huge Symptomatic Brenner Tumour Simulating Uterine Fibroid: A Case Report

Type of Article: Case Report

John .D. Ojule, Kinikanwo Green

Department of Obstetrics & Gynaecology, University of Port-harcourt Teaching Hospital, Port-harcourt, Nigeria.

ABSTRACT

Background

Brenner tumours are rare ovarian neoplasms which are frequently so small and symptomless as to be incidental findings at laparotomies for other conditions. The occurrence of a huge symptomatic Brenner tumour is even rarer in our environment. Our objective is to report a case of huge symptomatic Brenner tumour in a 67 year old post-menopausal woman and to alert practicing Gynaecologists that though rare, this condition still occurs and to re-emphasize the need for proper and routine histological examination of all surgical specimen.

Method

The case note of the patient who presented at the gynaecology clinic of the University of Port-Harcourt Teaching Hospital with 15 years history of abdominal swelling and pain and repeated ultrasound scan diagnosis of multiple uterine fibroids and managed in our centre, was retrieved and studied. Literature on the subject was also reviewed using available journals and online resources.

Results

The patient had exploratory laparotomy, total abdominal hysterectomy and bilateral salpingo-ovariectomy. Intraoperative findings were clean peritoneal cavity, a hard, 15cm diameter irregular right ovarian mass, slightly bulky uterus with 3cm long cervix, normal tubes and left ovary. The ovarian mass was confirmed histologically as benign Brenner tumour. She did remarkably well post-operatively and had since been discharged from the gynaecology clinic.

Conclusion

This case illustrates that even rarer huge symptomatic Brenner tumours still occur in our environment. Practicing Gynaecologists should be aware of this condition and the need for proper histologic examination of surgically removed specimen.

Keywords: Huge, symptomatic, Brenner Tumour, uterine fibroid.

CORRESPONDENCE: J.D. OJULE

INTRODUCTION

Brenner tumours are uncommon solid fibro-epithelial neoplasm, in which the proliferating epithelial element has a transitional cell appearance, representing

metaplasia¹. It accounts for 1-2% of all ovarian neoplasms.^{1,2} Although over 98% of these tumours are benign, and nearly 95% cases are unilateral, tumours of borderline malignancy (proliferative Brenner tumours), malignant and bilateral forms of these tumours have occasionally been reported.^{1,2,3} They are frequently so small as to be incidental findings at laparotomy, however very rarely it may grow up to 5-20cm in diameter and present as a pelvic mass at vaginal examination.^{1,4}

These tumours generally seen in women around menopause, are usually asymptomatic, but can rarely cause post-menopausal bleeding and may be associated with ascites and hydrothorax in the rare pseudo-Meigs' syndrome.⁵ Some have been reported to secrete estrogen which may be responsible for the abnormal vaginal bleeding.⁶

This case of huge symptomatic Brenner tumour is reported because of its rarity in our environment and the unusual presentation, repeatedly mis-diagnosed ultrasonographically as uterine fibroid in a 67 year old post-menopausal woman and to remind practicing clinicians that, though very uncommon, these neoplasms still occur.

Case report

Mrs. N.E. was a 67 year old post-menopausal farmer, para8⁺, who presented at the Gynaecology clinic with 15 years history of progressive abdominal swelling and pain. The swelling was initially noted at the suprapubic region, but gradually increased extending to the umbilical area, occasionally causing abdominal discomfort and pain relieved by simple analgesics. There were no urinary or gastro-intestinal symptoms. There was no history of chronic cough or weight loss. There was a previous history of occasional mild vaginal bleeding which stopped 6 years before presentation at the University of Port Harcourt teaching hospital (UPTH). There was no offensive vaginal discharge. Previous and recent ultrasound scan done just before presentation suggested multiple uterine fibroids with normal adnexae. She had been to several private hospitals before, where she persistently declined surgery. She eventually presented in UPTH for further management and surgery to enable her participate effectively in the burial of her husband who died few weeks before her presentation.

Her age at menarche was not known. She was 15 years post-menopausal. She had normal menstrual flow and cycle during her reproductive years. She did not practice contraception.

She had 8 confinements between 1960 and 1978 by spontaneous vaginal deliveries, all alive.

Her past medical and surgical history was not significant. She was a widow. There was no family history of systemic disease. She did not take alcohol or tobacco. There was nothing significant on review of her systems.

On physical examination, she was a healthy looking elderly woman, who was not febrile, pale or jaundiced. There was no peripheral lymphadenopathy.

Her chest was clinically clear. Her radial pulse rate was 80 beats per minute, regular and of full volume. The blood pressure was 130/80mmHg. Her heart sounds were normal.

Her abdomen was distended up to the level of the umbilicus and moved with respiration. There was no area of tenderness. There was an irregularly shaped, hard, non-tender, mobile mass, the size of a 22 weeks pregnancy. The liver, spleen and kidneys were not palpably enlarged. There was no demonstrable ascites.

The vulva and the vagina were normal. The uterus appeared to be 22 weeks size as described above. The adnexae were free. The cervix was about 3cm long and felt healthy. The pouch of Douglas was empty.

A provisional diagnosis of multiple uterine fibroids in a post-menopausal woman was made. A differential diagnosis of a solid ovarian tumour was also entertained. She was admitted into the gynaecological ward. Her packed cell volume was 38%. Two units of compatible blood were grouped and cross-matched for her. Her fasting blood sugar, liver and renal function test results were all normal. The urinalysis, echocardiogram and chest radiograph were also normal. A repeat abdomino-pelvic ultrasound scan done in UPTH "showed a bulky uterus for age with a heterogenous myometrial echotexture. There was a pedunculated mass arising from the fundus with a homogenous echotexture with areas of calcifications casting acoustic shadows and measuring 8.9 x 7.5cm. The endometrial plate was normal. No adnexial mass was seen. There was no fluid in the pouch of Douglas". An ultrasound diagnosis of a calcified uterine fibroid was made. She was counselled and readily agreed to our management plan of exploratory laparotomy and an informed consent obtained.

She had total abdominal hysterectomy and bilateral salpingoovariectomy for solid ovarian tumour. Intra operative findings were a clean peritoneal cavity, a huge, hard, irregular mass about 15cm in diameter, arising from the right ovary and extending to the slightly bulky uterus and the left adnexum, normal left ovary and fallopian

tubes. The estimated blood loss was 500ml. The specimen was sent for histopathological examination.

Her recovery from anaesthesia was uneventful. She received intravenous fluids, parenteral antibiotics and analgesics for 48 hours. The drugs were converted to the oral forms on the 2nd post-operative day when her bowel sounds returned. Her post-operative packed cell volume was 35%. The rest of her post-operative period remained uneventful and was discharged home 7th post-operative day in satisfactory clinical condition with a 2 week appointment.

She was seen two weeks later at the gynaecological clinic. She had no complaints and her general condition was satisfactory. The abdominal wound had healed satisfactorily. Other findings on systemic examinations were normal.

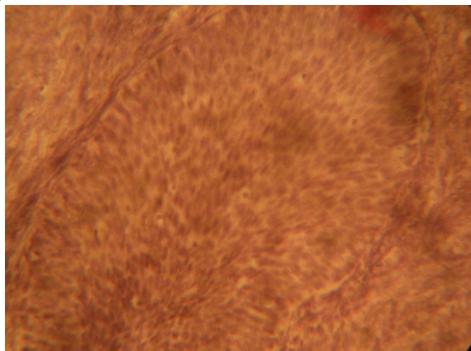
Histopathology on macroscopy showed an irregularly shaped multinodular mass with attached fallopian tubes. The surface was riddled with numerous nodules. The cut surface was nodulated, whorled and gritty. Uterus measured 6x5x2cm. Cervix is 3cm in length and was patulous. Microscopy showed interlocking bundles of smooth muscle fibres with areas of calcification. The endometrium was atrophic and the myometrium unremarkable. The right ovary showed nests of transitional cells within the ovarian stroma. The left fallopian tube was unremarkable. A section from the cervix showed an ectocervix with parakeratosis and dilated endocervical glands". A hispathological diagnosis of Brenner tumour of the ovary was made.

She was again counselled on the condition, re-assured and discharged from the gynaecology clinic.

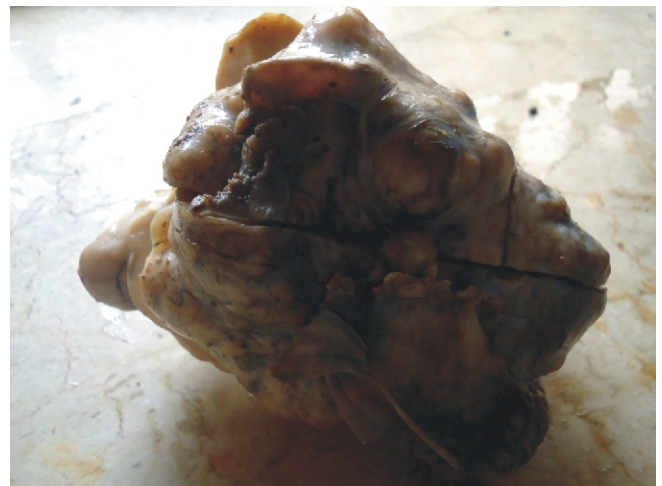

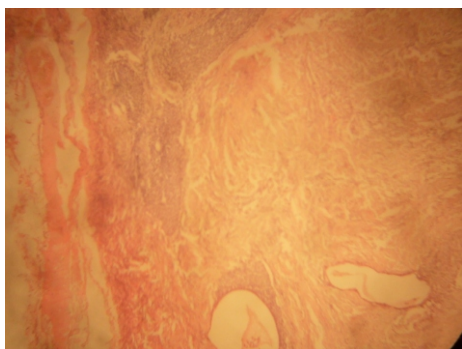
FIG 1. GIANT BRENNER TUMOUR

Fig.3. PHOTOMICROGRAPH OF THE BRENNER TUMOUR



H&E X400 Ovary with Brenners tumour showing a single transitional nest at high power with benign nuclei.

FIG. 4 PHOTOMICROGRAPH OF THE OVARY/BRENNERS TUMOUR



H&E X100 Ovary; same tissue showing nest of transitional like epithelium embedded within fibrous ovarian stroma. Less frequently, the nests contain microcysts or glandular spaces lined by columnar, mucin-secreting cells.

DISCUSSION

Brenner tumours are uncommon ovarian neoplasms whose aetiology and hormonal activity will continue to arouse controversies. The histogenesis has remained an enigma. The theory that this neoplasm develops from whalthards nests fails to reconcile the disparity between the anatomic disposition of such nests and the site of Brenner tumours.^{1,7} Other suggestions have included origin from germ cells, from germinal epithelium, from the rete ovarii, from follicular structures or from gonadal stroma, but perhaps the most acceptable is that the tumour is formed from the urinary tract epithelium, arising either from the mesonephric remnants or by metaplasia of the germinal epithelium.⁷ Certainly, the islands of Brenner tissues closely resemble transitional epithelium and this is seen even more clearly in the rare malignant Brenner tumours which mimic closely transitional cell carcinomas.⁷

These tumours which have also been reported to occur in extra-ovarian sites like the myometrium⁸ and the testis⁹, are usually about 2cm in diameter, symptomless and found incidentally during laparotomy for other conditions.^{1,6}

The case presented is unusual in several respects; initial
9.Laccaino D, Socias M, Truchet C. Malignant Brenner tumours of the testis and epididymis. Arch Pathol Lab Med 1991; 115(5): 524-527

postmenopausal bleeding which stopped spontaneously 6 years before presentation, slowly growing tumour, approximately 15cm in diameter, associated abdominal discomfort and pain, slightly bulky uterus, and ultrasound scan features repeatedly suggestive of uterine fibroid.

The abnormal vaginal bleeding resulting from endometrial hyperplasia has been attributed to stromal luteinization with estrogen production by the tumour.⁶ This may explain the initial post-menopausal bleeding in our patient, and the slightly bulky uterus and 3cm long cervix, which ordinarily should be atrophic in this 67 years old post-menopausal woman.

Management of Brenner tumour is similar to ovarian fibromas, with bilateral salpingo-oophorectomy recommended for post-menopausal women and simple excision with ovarian preservation being preferred for younger women who wish to preserve their fertility. Total abdominal hysterectomy and bilateral salpingo-ovariectomy was done for patient because of her menopausal state, slightly bulky uterus, and the possibility of malignancy.^{1,3} Prognosis is usually excellent for patients with Brenner tumours.⁶

CONCLUSION

This case illustrates that even rarer huge symptomatic Brenner tumours still occur in our environment. Practicing Gynaecologists should be aware of this condition and the need for proper histologic examination of surgically removed specimen.

REFERENCES

1. Purcell K, Wheeler JE. Benign disorders of the ovaries and oviducts. In: Decherney AH, Nathan L (eds). Current Obstetrics and Gynaecological Diagnosis & Treatment. 9th edition. McGraw-Hill Companies New York 2003: 708-715.
2. Ola ER. Tumours of the ovary. In: Agboola A (ed). Textbook of Obstetrics and Gynaecology for medical students. 2nd edition. Heineman books PLC, Ibadan: 2006; 197-224.
3. Marwah N, Mathus SK, Marwah S, Karwosa RK, Arora B. Malignant Brenner tumour: a case report. Indian J Pathol Microbiol 2005; 48(2): 251-252.
4. Green GE, Mortile KJ, Glickman JN, Benson CB. Brenner tumours of the ovary: sonographic and computed tomographic imaging features. J ultrasound Med 2006; 25(10): 1245-1251.
5. Padubidri MS, Daftary SN. Disorders of the ovary. Shaw's Textbook of Gynaecology. 13th edition. Elsevier, New Delhi: 2004; 352-372.
6. Girling JC, Soutter WP, Stanton SL (eds). Gynaecology. 2nd edition. Churchill Livingstone, London: 1997; 615-627.
7. Sternberg WH. Non-functioning ovarian neoplasms. In: Grady HG, Smith DE (eds). The Ovary. Williams and Wilkins, Baltimore: 1963; 209-215.
8. Lowe DG. Benign tumours of the uterus. In: Edmonds DK (ed). Textbook of Obstetrics and Gynaecology for Postgraduates. 6th edition. Blackwell Science, London: 1999; 552-559.